



## Contrast-induced nephropathy: Basic concepts, pathophysiological implications and prevention strategies☆



Charalampos Mamoulakis <sup>a,\*</sup>, Konstantinos Tsarouhas <sup>b,1</sup>, Irimi Fragkiadoulaki <sup>c,1</sup>, Ioannis Heretis <sup>a</sup>, Martin F. Wilks <sup>d</sup>, Demetrios A. Spandidos <sup>e</sup>, Christina Tsitsimpikou <sup>f</sup>, Aristides Tsatsakis <sup>c</sup>

<sup>a</sup> Department of Urology, University General Hospital of Heraklion, University of Crete, Medical School, Heraklion, Crete, Greece

<sup>b</sup> Department of Cardiology, University General Hospital of Larisa, Larissa, Greece

<sup>c</sup> Department of Forensic Sciences and Toxicology, Faculty of Medicine, University of Crete, Heraklion 71003, Greece

<sup>d</sup> Swiss Centre for Applied Human Toxicology, University of Basel, CH-4055 Basel, Switzerland

<sup>e</sup> Department of Virology, Medical School, University of Crete, Heraklion, Crete, Greece

<sup>f</sup> Department of Hazardous Substances, Mixtures and Articles, General Chemical State Laboratory of Greece, Ampelokipi, Athens, Greece

### ARTICLE INFO

Available online 19 June 2017

#### Keywords:

Contrast media

Kidney

Nephropathy

Prevention

Toxicity

### ABSTRACT

Contrast-induced nephropathy (CIN) is reversible acute renal failure observed following administration of iodinated contrast media (CM) during angiographic or other medical procedures such as urography. There are various mechanisms through which CM develop their nephrotoxic effects, including oxidative stress and apoptosis. CIN is a real-life, albeit not very rare, entity. Exact pathophysiology remains obscure and no standard diagnostic criteria apply. The Acute Kidney Injury Network criteria was recently employed but its incidence/clinical significance warrants further clarification based on recent methodological advancements, because most published studies to date were contaminated by bias. The current study is a comprehensive review conducted to provide an overview of the basic concepts of CIN and summarize recent knowledge on its pathophysiology and the evidence supporting potential prevention strategies. CIN is expected to increase morbidity, hospital stay and mortality, while all patients scheduled to receive CM should undergo risk assessment for CIN and high-risk patients may be considered candidates for prevention strategies. The value of using compounds with antioxidant properties other than sodium bicarbonate, remains controversial, warranting further clinical investigation.

© 2017 Elsevier Inc. All rights reserved.

### Contents

1. Introduction . . . . .	100
2. Objective and methods of the review . . . . .	101
3. Terminology . . . . .	101
4. Incidence of CIN . . . . .	101
5. Pathophysiology of CIN . . . . .	102
6. Risk factors of CIN . . . . .	103
7. Prevention strategies for CIN . . . . .	106
8. Conclusions . . . . .	109
Conflict of interest statement . . . . .	109
References . . . . .	109

*Abbreviations:* AKI, Acute kidney injury; BUN, Blood urea nitrogen; CIN, Contrast-induced nephropathy; CM, Contrast medium/media; GFR, Glomerular filtration rate; KIM-1, Kidney injury molecule-1; L-NAME, (N<sup>w</sup>-nitro-L-arginine methyl ester); MDA, Malondialdehyde; NGAL, Neutrophil gelatinase-associated lipocalin; ROS, Reactive oxygen species; sCr, Serum creatinine; SOD, Superoxide dismutase.

☆ Associate editor: L.H. Lash.

\* Corresponding author.

E-mail address: [mamoulak@uoc.gr](mailto:mamoulak@uoc.gr) (C. Mamoulakis).

<sup>1</sup> Equal contribution of authors.

## 1. Introduction

Contrast-induced nephropathy (CIN) is reversible acute renal failure observed after administration of iodinated contrast media (CM) during angiographic or other medical procedures such as urography. The expected increase of serum creatinine (sCr) generally appears within 48 h after CM exposure, reaching a peak within the following 5 days. Increased morbidity, hospital stay and mortality is often associated with CIN (Golshahi, Nasri, & Gharipour, 2014; Rewa & Bagshaw, 2014). CIN has a considerable prevalence that reaches 15% in high-risk patients (see below; Section 6. Risk factors of CIN), whereas in ordinary patients the incidence does not exceed 1% (Rancic, 2016).

CM are non-reabsorbable solutes of high-, low- or isoosmolality, which act as osmotic diuretics, reducing electrolyte re-absorption along the nephron and thereby causing an increase in urine output (Solomon, 2014). Iodinated CM can be ionic or non-ionic, depending on their solubility in water. First generation CM have really high osmolalities (around 1000–2500 mOsm/kg) compared to plasma (290 mOsm/kg), due to the fact that osmolality, molar concentration and ionic strength are directly proportional quantities (Pannu, Wiebe, Tonelli, & Alberta Kidney Disease, 2006). The second generation CM were mainly characterised by lower solution osmolality of around 400–800 mOsm/kg, through formation of ionic dimers (ioxaglate) or non-ionic monomers (iopromide, iopamidol, iohexol, ioversol) (Pannu et al., 2006). The final step in evolution was the development of isoosmolar CM, such as iodixanol and iotrolan, which are non-ionic dimeric compounds. Pure low-osmolar CM solutions are actually hypo-osmolar. Therefore, in order to reach plasma osmolality electrolytes are added (Jost et al., 2011).

The osmotic properties of CM could account for numerous hemodynamic alterations, including vasodilatation, increases in circulating blood volume and peripheral blood flow, and decreases in systemic resistance (hypotension) (McClennan, 1990). Hemodilution effects result from extravascular water shifts into the bloodstream that contribute to some of the hemodynamic perturbations associated with high-osmolar CM administration. Red blood cell changes (crenation and rigidity) and endothelial damage directly at the injection site accompanied by release of vasoactive substances, such as serotonin, histamine, prostaglandins, fibrinolysins, kallikreins, leukotrienes, bradykinin etc., may lead to hemodynamically altered microcirculation or other physiologic changes that may cause side effects. Some hemodynamic effects can be related

to osmolality and to a lesser degree to the chemotoxic properties of the CM. These include negative inotropic effects and decrease in myocardial contractility after intra-cardiac injections. Decreased cardiac output and increased pulmonary artery pressure may occur along with plasma volume changes noted previously. Effects on the cardiac conduction system may result in abnormal electrocardiogram patterns, some of which may be clinically significant depending on the underlying cardiovascular status.

Reduction of osmolality in modern CM has ameliorated their safety profile (Caiazza, Russo, Sabbatini, & Russo, 2014) at the expense of increased viscosity (Jost et al., 2011). Viscosity strongly depends on iodine concentration of the solution, increasing exponentially (Seeliger et al., 2007) and strongly influences renal side-effects. CM with higher viscosity increase urine viscosity leading to higher tubular pressure that causes low urine flow rate and clearance, which in their turn prolong bioavailability, leading to a more pronounced tubular injury (Seeliger et al., 2010; Ueda, Nygren, Hansell, & Ulfendahl, 1993). High osmolality could actually reduce exposure through osmotic diuresis and in vitro dilution (Lenhard et al., 2012). Animal studies have shown that during administration of high viscosity isoosmolar CM, osmotic diuresis is missing and the dwelling time of CM in the urinary tubules and thus their bioavailability is higher (Jost, Pietsch, Lengsfeld, Hutter, & Sieber, 2010) (Fig. 1).

To mitigate this effect, current practice mandates a) right choice of the agent, b) heating of low-osmolar/isoosmolar CM before use because viscosity is inversely proportional to temperature and c) aggressive hydration around the time of exposure to dilute the agents and decrease their viscosity (Dorval et al., 2013). Most medical centres no longer use intravascular, high-osmolar CM to avoid various adverse effects associated with their use (ACR Committee on Drugs and Contrast Media, 2016). A meta-analysis showed that in patients with underlying renal insufficiency, nephrotoxicity of CM with low-osmolality is lower compared to high-osmolar CM (Barrett & Carlisle, 1993). It is not clear yet whether intravenous low-osmolar or isoosmolar CM (iodixanol) are less detrimental regarding CIN (Dong, Jiao, Liu, Guo, & Li, 2012; McCullough & Brown, 2011). According to the European Society of Cardiology and the European Association for Cardio-Thoracic Surgery guidelines (Authors/Task Force members, 2014), for patients with moderate-to-severe chronic kidney disease undergoing coronary angiography or multi-detector computed tomography, CM volume should be minimized and isoosmolar should be considered over low-osmolar

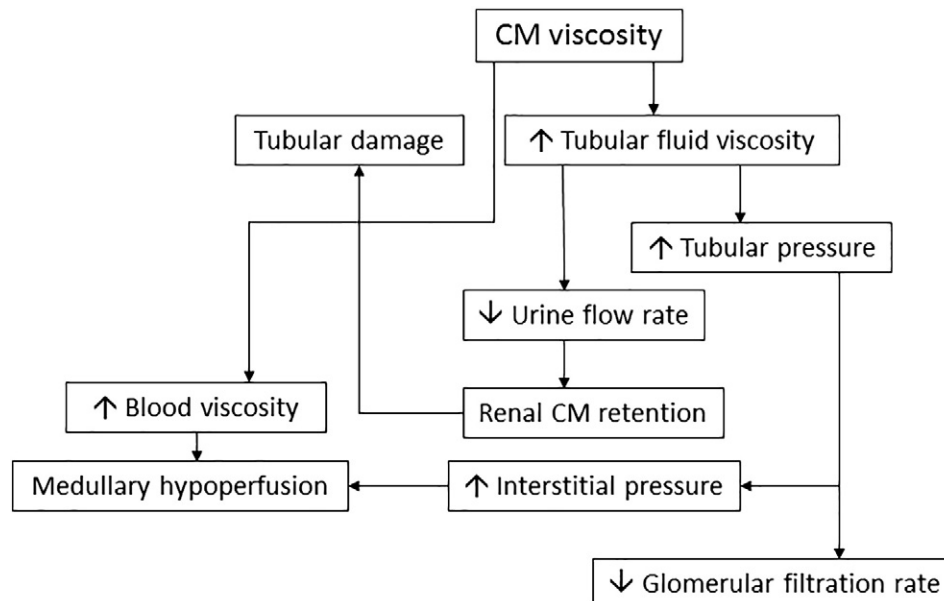


Fig. 1. Simplified scheme depicting the basic mechanism of CM viscosity-induced damage (Seeliger et al., 2012).

agents at the recommended dose for both of them <350 mL or <4 mL/kg or total contrast volume/glomerular filtration rate (GFR) <3.4. According to the American College of Radiology guidelines (ACR Committee on Drugs and Contrast Media, 2016), extrinsic warming to human body temperature (37 °C) of iodinated CM could minimize complications and improve vascular opacification in certain applications, such as high-rate (>5 mL/s) intravenous low-osmolar CM power injections; viscous iodinated agent injections (e.g., iopamidol 370); and direct arterial injections using small catheters (≤5 Fr). According to the American College of Radiology and the European Society of Cardiology/European Association for Cardio-Thoracic Surgery guidelines, intravenous volume expansion with isotonic fluids prior to CM administration could prevent the risk of CIN (see below) (ACR Committee on Drugs and Contrast Media, 2016; Authors/Task Force members, 2014) (Table 1).

## 2. Objective and methods of the review

The literature was screened up to November 2016 to select publications focusing on the topic “contrast-induced nephropathy” with due emphasis given to relevant reviews summarizing developments during the past five years. Medline, Science Citation Index, and the Cochrane Library were searched, using the following key words: *N*-acetylcysteine (NAC); antioxidants; ascorbic acid; CM; fluid therapy; nephropathy; nitric oxide; oxidative stress; ROS; and sildenafil citrate either in the title, abstracts, or in the text. The relevance of the subject and eligibility of all publications detected was further evaluated based on the title and abstract. Data were then extracted from selected papers and discussed among the authors. A final version of the manuscript was prepared after several draft revisions and approved by all authors.

## 3. Terminology

CIN describes a sudden deterioration in kidney function occurring within 48 h after intravascular administration of iodinated CM, which is due to the CM. On the other hand, post-contrast acute kidney injury (AKI) describes a sudden deterioration in kidney function occurring within 48 h after intravascular administration of iodinated CM regardless of the cause (Baumgarten & Ellis, 2008; Davenport, Cohan, Khalatbari, & Ellis, 2014; Davenport et al., 2013; Katzberg & Newhouse, 2010; McDonald et al., 2013, 2014; Newhouse & RoyChoudhury, 2013). Therefore, *CIN is a causative diagnosis, while post-contrast AKI is a correlative diagnosis* and the two terms are neither

synonymous nor interchangeable (ACR Committee on Drugs and Contrast Media, 2016). Consequently, CIN is a subgroup of post-contrast AKI but few studies could allow differentiation thereof mainly due to the control group selection (Baumgarten & Ellis, 2008; Davenport et al., 2013, 2014; Katzberg & Newhouse, 2010; McDonald et al., 2013, 2014; Newhouse & RoyChoudhury, 2013). As a result, the incidence of cases reported in clinical studies and observed in clinical practice probably combines CIN (i.e. AKI caused by CM administration) and other AKI cases not caused by CM administration.

## 4. Incidence of CIN

CIN is generally considered a reversible form of acute renal failure that begins soon after iodinated CM administration during angiographic or other procedures such as urography and it is recognized as an increase of sCr level that generally appears in the first 48 h after exposure to the CM and reaches a peak within the next 5 days (Wi et al., 2011). CIN is associated with increased morbidity, hospital stay and mortality (Golshahi et al., 2014; Rewa & Bagshaw, 2014). There are no standard criteria for CIN or post-contrast AKI diagnosis; in the past sCr has been widely used, either as 25% to 50% increase of the baseline sCr levels and/or an absolute elevation of 0.5 to 2.0 mg/dL from baseline (ACR Committee on Drugs and Contrast Media, 2016). However, sCr is not a real-time biomarker of changing renal function. It rises slowly, relative to the amount of filtration function lost in contrast-induced nephropathy, delaying diagnosis by an average of 48–72 h. Changes in sCr concentration are not sensitive or specific for small alterations in GFR (Sterling, Tehrani, & Rudnick, 2008). The decline in kidney function usually occurs 1 to 3 days after the procedure. Renal function usually returns to pre-existing levels within 7 days (Barrett & Parfrey, 2006).

Early identification of patients with AKI being at high risk for adverse outcome can influence medical treatment. In general, CIN may be monitored either by biomarkers representing changes in renal function (e.g., sCr or cystatin C and urine flow rate) or by those reflecting kidney damage (e.g., Kidney injury molecule-1 (KIM-1), Neutrophil gelatinase-associated lipocalin (NGAL), interleukin-18, etc.). KIM-1 is a transmembrane protein not expressed in normal kidney but upregulated in dedifferentiated proximal tubule cells after ischemic or nephrotoxic AKI. Serum neutrophil gelatinase-associated lipocalin (NGAL), a ubiquitous 25 kDa protein, covalently bound to gelatinase from human neutrophils, is a marker of tubular injury (Briguori, Quintavalle, Donnarumma, & Condorelli, 2014). KIM-1 may be used

**Table 1**

Iodinated CM: an overview (ACR Committee on Drugs and Contrast Media, 2016; Solomon, 2014; Susantitaphong & Eiam-Ong, 2014).

Generation	Examples	Osmolality	Ionicity	Iodine to molecule ratio	Administration	Uses	Clinical aspects of application
1st (first application in the 1920s)	Diatrizoate Iothalamate Metrizoate	High	Ionic monomer	1.5:1	Oral Intravenous Urologic Gastrointestinal	CT X-ray Fluoroscopy Retrograde or ascending pyelography Cystography	✓ Nonvascular procedures ✓ Not-widely used ✓ Patients' hydration highly recommended
2nd (first application in the 1960s)	Ioxaglate Iohexol Iopamidol Iopromide Iomeprol	Low	Ionic dimer Nonionic monomer	3:1	Intravenous Intrathecal Oral	Angiocardiology Arteriography of cerebral arteries CT of the head Digital subtraction angiography Pyelography Peripheral angiography	✓ Indication for patients with renal insufficiency compared to high-osmolar CM ✓ Heating to reduce viscosity ✓ Iohexol and ioxaglate show significantly higher risk for CIN than other high-osmolar CM ✓ Hydration highly recommended
3rd (first application in the 2000s)	Iodixanol Iotrolan	Iso	Nonionic dimer	6:1	Intravenous	Angiocardiology Multi-detector computed tomography	✓ Indication for high risk patients ✓ Indication for patients with moderate-to-severe kidney disease over low-osmolar CM ✓ Heating to reduce viscosity recommended ✓ Hydration highly recommended

for early diagnosis and early initiation of treatment, as well as NGAL, which starts to raise at 6 h after CM exposure (Akdeniz et al., 2015; Briguori, Donnarumma, Quintavalle, Fiore, & Condorelli, 2015; Han, Bailly, Abichandani, Thadhani, & Bonventre, 2002). In addition, urinary KIM-1 can be useful for the prediction of renal injury, while urinary NGAL has a good diagnostic performance in predicting mortality in pediatric patients with CIN of heterogeneous etiology (Westhoff et al., 2017). On the other hand, in a recent study KIM-1 and NGAL excretion were unaffected by intravenous CM administration (Kooiman et al., 2015). In conclusion, there are still open issues in the area of predicting and monitoring CIN, such as the optimum biological specimen collected (urine versus blood), the sampling time, the cutoff value (or threshold) of various novel markers and the clinical and prognostic significance of this kidney injury biomarker in the setting of CIN.

Reported cases of post-contrast AKI vary considerably, as the numeric criterion of sCr change varies, too. Furthermore, due to low sensitivity/specificity, sCr increase cannot differentiate CIN from generic post-contrast AKI (ACR Committee on Drugs and Contrast Media, 2016), either in cohort studies with problematic control groups or during clinical evaluations of individual patients (Davenport et al., 2013, 2014; McDonald et al., 2013, 2014; Newhouse & RoyChoudhury, 2013). The Acute Kidney Network consensus group addressed the variable definitions of AKI attempting to standardize the diagnosis/staging irrespective of etiology (Mehta et al., 2007). According to the criteria developed, AKI is diagnosed if within 48 h after a nephrotoxic event (e.g., intravascular iodinated CM exposure), one of the following is observed (Mehta et al., 2007): i) absolute sCr increase  $\geq 0.3$  mg/dL ( $>26.4$   $\mu\text{mol/L}$ ); ii) % increase in sCr  $\geq 50\%$  ( $\geq 1.5$ -fold above baseline); iii) urine output reduced to  $\leq 0.5$  mL/kg/h for at least 6 h.

The Acute Kidney Injury Network criteria can be used to define the parameters of both post-contrast AKI and CIN. However, only recently have they been employed scientifically in CIN investigation (Baumgarten & Ellis, 2008; Chousterman et al., 2013; Davenport et al., 2013; Endre & Pickering, 2010; Lakhali et al., 2011). The incidence and clinical significance of CIN definitely warrants further clarification by future investigations based on recent methodological advancements (Davenport et al., 2013; de Caestecker et al., 2015; McDonald et al., 2013, 2014), because published studies to date have been severely affected by bias and conflation (ACR Committee on Drugs and Contrast Media, 2016).

## 5. Pathophysiology of CIN

The exact pathophysiology of CIN is obscure (ACR Committee on Drugs and Contrast Media, 2016) and several factors may be implicated, including renal ischemia, particularly in the medulla, reactive oxygen species (ROS) formation, reduction of nitric oxide production, and tubular epithelial and vascular endothelial injury (Andreucci, Faga, Pisani, Sabbatini, & Michael, 2014; Scoditti, Massaro, & Montinari, 2013) (Fig. 2). Iodinated CM may exert their nephrotoxic effects in several ways. Hemodynamic alterations resulting in renal medullary hypoxia and direct toxicity on renal tubular epithelial cells seem to be major factors contributing to CIN (Caiazza et al., 2014). All types of CM exert cytotoxic effects in vitro and renal tubular epithelial cells present signs of severe cell damage or apoptosis when exposed to CM (Romano et al., 2008; Seeliger, Sendeski, Rihal, & Persson, 2012). CM induce renal vasoconstriction, through increase of adenosine and endothelin, and deflect blood flow from the medulla to the cortex. Consequently, renal blood flow to the medulla and GFR are reduced, followed by renal medullary ischemia (Persson, Hansell, & Liss, 2005).

Reduction in renal blood flow can also activate ROS release through oxidative stress and osmotic necrosis or vacuolization caused directly by the CM in tubular cells, leading to acute tubular necrosis (Keaney, Hannon, & Murray, 2013; Tumlin et al., 2006). ROS constrict renal microcirculation and indirectly affect renal vascular tone by mediating the effects of other vasoconstrictors, stimulating the production of

vasoconstrictors and modulating the actions of vasodilators, such as nitric oxide (Briguori, Quintavalle, De Micco, & Condorelli, 2011). Mitochondrial dysfunction as a result of direct tubular toxicity, in combination with ROS generation, damages glomerular cells by increasing the membrane permeability leading to apoptosis (Goldenberg & Matetzky, 2005; Romano et al., 2008). Apoptosis, after CM administration, can also be caused by activation of stress kinases and by the intrinsic apoptosis pathway (Ramponi, Grotti, Morisetti, Vultaggio, & Lorusso, 2007).

More specifically, renal hypoxia in the setting of CM administration is considered a crucial factor in the generation of ROS in the kidney (Pisani et al., 2013). However, there are conflicting reports whether oxidative stress is a result of CM renal injury or actually contributes to nephropathy development. Advocates of ROS causal implication in the pathophysiology of CIN consider that CM administration is responsible for toxic renal parenchymal injury, which is presumably mediated by ROS. Current research is focused on delineating ROS involvement in the pathophysiology of CIN and the potential intervention in ameliorating it. Table 2 presents a summary of recent experimental studies on oxidative stress related to CIN in animal models (Table 2a) and humans (Table 2b).

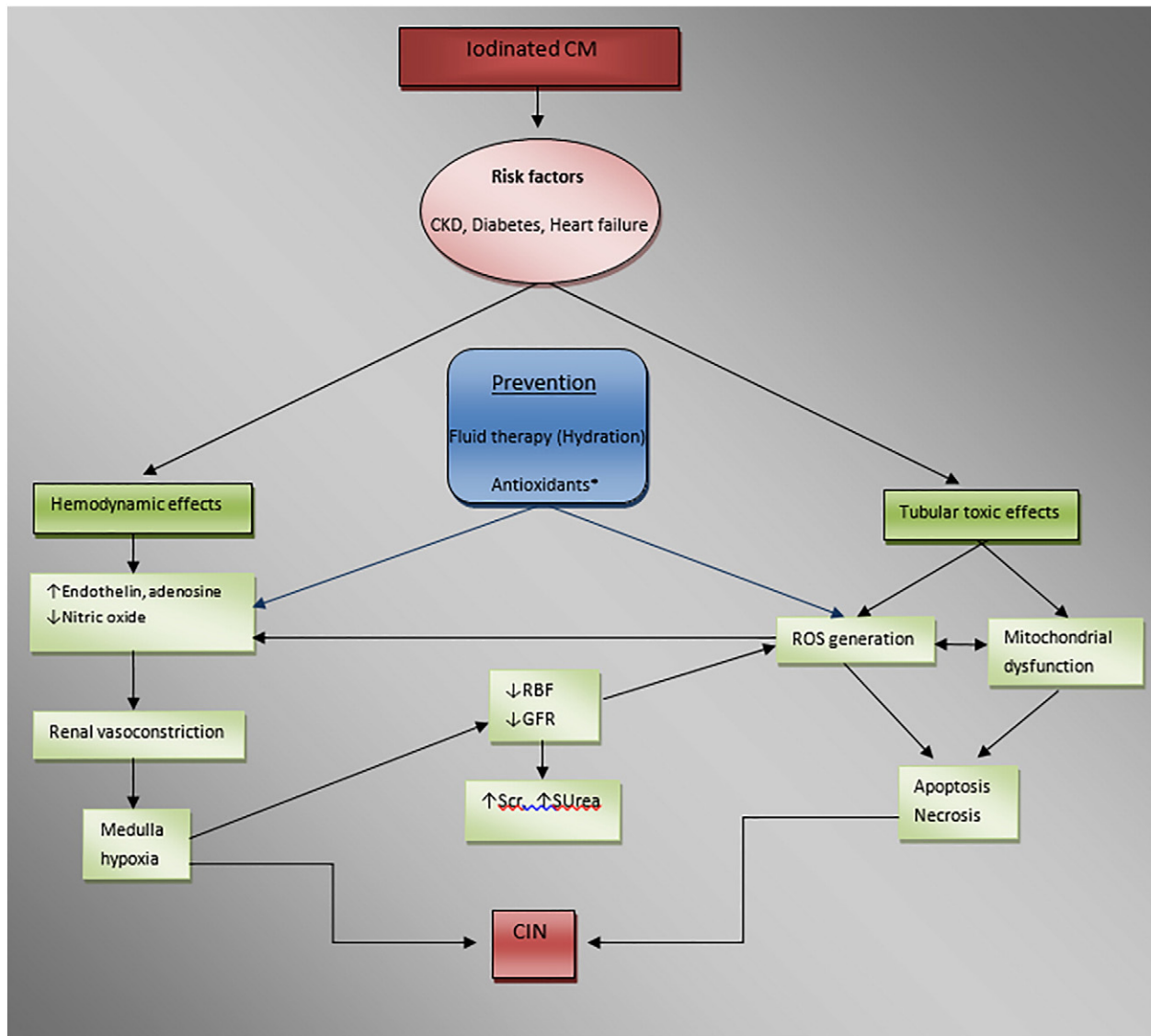
ROS, such as superoxide ( $\text{O}_2^-$ ), hydrogen peroxide ( $\text{H}_2\text{O}_2$ ) and hydroxyl radical ( $\text{OH}^-$ ), are actively involved in inflammatory responses. ROS are generated during renal parenchymal hypoxia induced by CM causing direct tubular and vascular endothelial injury. This in turn can aggravate renal parenchymal hypoxia augmenting endothelial dysfunction and dysregulation of tubular transport (Pisani et al., 2013). Free oxygen radicals lead to the accumulation of peroxynitrite, which is oxidative and a very reactive nitrosative species capable of further reducing the bioavailability of nitric oxide. The adverse effect occurs through the nitrosation of tyrosine residues of enzymes, such as prostacycline synthase and nitric oxide synthase, which are involved in the synthesis of medullary vasodilators. As a result, greater vasoconstriction and increased tissue damage can occur (Detrenis, Meschi, Musini, & Savazzi, 2005).

On the other hand, ROS activate c-Jun N-terminal kinases (JNKs) and p38 MAPK stress kinases, which contribute to the activation of caspase-9 and caspase-3 (Briguori et al., 2015). The induction of apoptosis is associated with the activation of aspartate-specific cysteine proteases. Mitochondria play a role in some forms of apoptosis by releasing cytochrome c and activating caspase-9, which activates caspase-3. Caspase-3, as a common component of apoptotic signaling, mediates both mitochondria-dependent and death receptor-dependent apoptosis pathways (Rezaee et al., 2016).

The ability to accommodate oxidative injury decreases with age and is thought to contribute to the increased risk of CIN among older patients, while increased oxidative stress is also present in chronic renal failure and in diabetes, known risk factors for CIN (Tumlin et al., 2006), as discussed later. The renal medulla has a unique circulatory anatomy (Liu, Schmerbach, et al., 2014), which causes medullary thick ascending limbs of the loop of Henle to perform energetically demanding ion transport in a situation of relative hypoxia compared with the renal cortex. It is thought that a mismatch between the metabolic demands of thick ascending limbs of the loop of Henle and the medullary blood supply could cause a surplus of superoxide ( $\text{O}_2^-$ ), leading to oxidative tubular damage superimposed on ischemic damage (Liu, Schmerbach, et al., 2014). Tubular transport is associated with ROS formation, mostly in the renal medullary thick ascending limb. The regional extremely dense mitochondrial population there represents a major source for generation of superoxide anions ( $\text{O}_2^-$ ) and hydroxyl radicals ( $\text{OH}^-$ ) by NAD(P)H-oxidase [nicotinamide adenine dinucleotide (phosphate) oxidase] (Pisani et al., 2013).

Oxidative DNA damage in renal tubular cells due to CM administration can lead to necrosis or apoptosis of these cells. DNA damage causes release of the p53 protein complex that, apart from its anticancer function, plays a role in apoptosis, genomic stability, and inhibition of





**Fig. 2.** Pathophysiology of CIN. Several factors, such as renal ischemia, particularly in the medulla, ROS formation, reduction of nitric oxide production, tubular epithelial and vascular endothelial injury are interconnected. CM: contrast media, CKD: chronic kidney disease, RBF: renal blood flow, GFR: glomerular filtration rate, Scr: serum creatinine, SUrea: serum urea, ROS: reactive oxygen species. Antioxidants\*: sodium bicarbonate, NAC, ascorbic acid, statins, phosphodiesterase type 5 inhibitors.

angiogenesis. In cases where genotoxic stress is found, p53 induces the expression of BIK (BCL2 Interacting Killer), a pro-apoptotic BH3-only member of the BCL-2 protein family. BIK is highly involved in the intrinsic apoptotic pathway leading ultimately to mitochondrial membrane dysfunction, mitochondrial fragmentation and release of cytochrome c (Mathai, Germain, & Shore, 2005). Recently in AKI animal models, p53 overexpression was noted and an equivocal role of the said molecule in renal cell apoptosis or autophagy was suggested (Ishihara et al., 2013). On the other hand, a direct toxic effect of CM to tubular cells leads to endoplasmic reticulum stress, which can cause cytosolic  $Ca^{2+}$  accumulation and calpain-1 and -2 activation leading to either activation of caspases or lysosome rupture, cathepsin release or PARP-1 cleavage and ultimately new DNA damage (Naziroglu, Yoldas, Uzgur, & Kayan, 2013). In the said context, calpain activation was found to promote glomerulonephritis (Peltier et al., 2006) while administration of calpain inhibitor-1 reduced renal insults in a rat model of renal ischemia/reperfusion injury (Chatterjee et al., 2001).

A novel and interesting pathway of antioxidant defense in CIN that was recently investigated involves the transcription factor nuclear factor erythroid 2-related factor 2 (Nrf2). Nrf2, when translocated into the nucleus, stimulates transcription of genes that encode detoxifying

and antioxidant enzymes, such as NADPH-quinone oxidoreductase 1 (NQO1) and GSH (glutathione) and peroxiredoxin I. All these enzymes contribute to cellular protection by removing superoxide anions, hydrogen peroxide and hydroxyl radicals (Saito, 2013). In this framework, sulforaphane, which is a widely used Nrf2 activator, was tested recently in CIN protection. Pre-treatment with sulforaphane attenuated renal damage and improved sCr concentration in an animal model of CIN (Zhao et al., 2016).

## 6. Risk factors of CIN

Multiple risk factors for CIN have been proposed, including among others diabetes mellitus; dehydration; cardiovascular disease; diuretic use; multiple myeloma; hypertension; hyperuricemia; and multiple iodinated CM doses within a short time (<24 h); female gender; advanced age; the amount and type of the contrast medium as well as the type of the intervention for which CM is used (Abujudeh, Gee, & Kaewlai, 2009; ACR Committee on Drugs and Contrast Media, 2016; Davenport et al., 2013; Heyman, Rosenberger, Rosen, & Khamaisi, 2013; Katsiki, Athyros, Karagiannis, & Mikhailidis, 2015; Russo, Aurelio, & Durante, 2014; Stacul et al., 2011; Trivedi & Foley, 2010; Weisbord & Palevsky, 2015).

**Table 2a**  
Recent experimental studies on oxidative stress markers related to CIN in animal models.

Animals	Study design	Main findings related to ROS	Kidney function
Wistar albino rats; Ari et al. (2012)	Contrast-induced nephropathy (CIN) by indomethacin, N <sup>w</sup> -nitro-L-arginine methyl ester (L-NAME) and meglumineamidotrizoate paracalcitol in controls	Paracalcitol + CIN group: lower serum malondialdehyde and lower kidney thiobarbituric acid-reacting substances	Paracalcitol + CIN group: lower mean serum creatinine (sCr) levels
Male Sprague-Dawley rats; Tasanarong, Kongkham, et al. (2014)	CIN induced by indomethacin, L-NAME and Iopromide. Phyllanthusemblica in CIN group and controls	Malondialdehyde (MDA) increase; decrease in total antioxidant capacity (TAC), superoxide dismutase (SOD) and catalase (CAT) activity in CIN group compared to controls. Rats treated with phyllanthusemblica showed lower MDA, higher TAC, SOD and CAT compared to CIN group	Phyllanthusemblica significantly preserved renal function/attenuated histological damage severity
Uni-nephrectomized rats; Pisani et al. (2014)	Recombinant manganese SOD in CIN group induced by indomethacin/diatrizoate	ROS doubled in CIN group compared to controls; normalized in recombinant manganese SOD group, significant SOD activity increase observed	Significant fall in glomerular filtration rate (GFR) – lower presence of tubular necrosis/intratubular casts in recombinant manganese SOD-treated rats
Male rats; Baykara et al. (2015)	CIN induced by diatrizoate; pretreatment with propolis, N-acetylcysteine (NAC) and calpain	Diatrizoate decreased glutathione, SOD, glutathione peroxidase, and CAT levels; normalization by pretreatment with propolis, NAC, calpain	Diatrizoate increased sCr, blood urea nitrogen (BUN) levels; propolis, NAC, calpain normalized sCr levels
Male Sprague-Dawley rats; Wang et al. (2014)	CIN induced by indomethacin, L-NAME and Ioversol. Subcutaneous injection of Magnolin	Elevated MDA/decreased SOD in CIN group compared to control. Pretreatment with Magnolin reduced MDA/increased SOD levels	Magnolin ameliorated tubular necrosis, apoptosis and deterioration of renal function
Sprague-Dawley rats; Zhao et al. (2015)	CIN induced by indomethacin, L-NAME and Ioversol. Pretreatment with recombinant renalase	Pretreatment with recombinant renalase decreased renal MDA levels and increased renal SOD levels	Increases in sCr and BUN were by recombinant renalase
Wistar rats; Wang, Wei, et al. (2015)	CIN induced by indomethacin, L-NAME and Iopromide. Probuco or NAC in CIN groups.	MDA level increased and SOD level decreased, significantly in the CIN group. Probuco and NAC: significantly milder changes in the above indices	Probuco and NAC groups: significantly lower sCr, BUN and urine protein levels compared to CIN group
Male Swiss mice; Boa et al. (2015)	CIN induced by indomethacin, L-NAME and Ioversol. Pretreatment with resin from <i>Virolaoleifera</i> or NAC	Marked increase in ROS production in the CIN group, compared with control. Highest dose of resin restored ROS in the medulla as effective as NAC.	Resin treatment had beneficial effects on renal histopathology superior NAC
Female Wistar albino rats; Ozbek et al. (2015)	CIN induced by meglumine/sodium diatrizoate. Tadalafil post CM	MDA levels significantly higher in CIN group compared to controls and tadalafil group	Serum cystatin C, sCr and BUN significantly lower in tadalafil group
Male Wistar rats; de Almeida et al. (2016)	CIN induced by water deprivation, L-NAME intraperitoneally and intravenous Iohexol. Sildenafil pretreatment in CIN groups	Sildenafil attenuated the increase in H <sub>2</sub> O <sub>2</sub> and ONOO <sup>-</sup> /OH <sup>-</sup> bioavailability without modifying the amount of O <sup>2-</sup> and nitric oxide	Sildenafil attenuated marked reduction of GFR and renal blood flow in CIN group
Sprague-Dawley rats; Zhao et al. (2016)	CIN induced by indomethacin, L-NAME and Ioversol. Sulforaphane in CIN group.	MDA in Ioversol group was significantly higher than controls. Sulforaphane significantly attenuated MDA levels increase; MDA levels did not significantly differ between control and Ioversol + sulforaphane groups	sCr and BUN decreased in the Ioversol + sulforaphane group compared to the Ioversol group
Female Wistar-albino rats; Cetin et al. (2008)	CIN induced by sodium Ioxithalamate + meglumineioxithalamate. Cisplatin and ascorbic acid in CIN groups	MDA increased significantly in CIN groups compared to controls. Ascorbic acid prevented the increase	CM + cisplatin caused increases in sCr creatinine and BUN. Significant reduction of tubular damage in rats treated with ascorbic acid
Male Sprague-Dawley rats; Colbay et al. (2010)	CIN induced by diatrizoate. Caffeic acid phenethyl ester and NAC in CIN groups	MDA levels of caffeic acid phenethyl ester and NAC groups were lower than CIN group. SOD and glutathione peroxidase activities were significantly lower in CIN group compared with other groups. CAT in the caffeic acid phenethyl ester CAPE group were significantly lower than NAC group	Renal injury scores higher in caffeic acid phenethyl ester and NAC groups than in control but lower than the CIN group. sCr levels in caffeic acid phenethyl ester and NAC groups were significantly lower than CIN group
Male Wistar rats; Kurtoglu et al. (2015)	CIN induced by water deprivation + diatrizoate. Ozone (O <sub>3</sub> ), or oxygen (O <sub>2</sub> ) pretreatment in CIN groups	No significant differences in MDA levels between the CIN and O <sub>2</sub> groups. MDA levels in CIN and O <sub>2</sub> groups were significantly increased compared with O <sub>3</sub> group	Prominent tubular necrosis in CIN group. sCr, BUN, tubular necrosis decreased in O <sub>3</sub> compared to CIN group
Male Wistar rats; Boyacioglu et al. (2014)	CIN induced by water deprivation and Iohexol Pretreatment with L-carnitine	MDA levels increased in CIN group. Compared with CIN group, glutathione levels were significantly higher in CIN + L-carnitine group. Compared with CIN group, SOD activities of the control and CIN + L-carnitine groups increased insignificantly.	Histopathological findings showed that L-carnitine may have a preventative effect in alleviating the negative effects of CIN
Sprague-Dawley rats; Hsu, Li, Chu, Periasamy, & Liu (2011)	CIN induced by Iothalamatemeglumine. Pretreatment with sesame oil and gentamicin s.c. for 5 days	Sesame oil significantly inhibited renal lipid peroxidation induced by the contrast and gentamicin combination. MPO level in contrast + gentamicin group was significantly higher than other groups	Sesame oil significantly prevented the rise of BUN and sCr levels
Wistar rats (normal and diabetic); Lee, Yen, & Sheu (2006)	CIN induced by ionic high-osmolardiatrizoate, ionic low osmolarioxaglate and non-ionic low osmolariopromide. Evaluation of glutathione peroxidase and SOD activity in heart and kidney tissue	Renal glutathione peroxidase activity significantly decreased in both normal and diabetic rats at 1 h after diatrizoate injection while renal SOD activities were not affected. Ioxaglate and Iopromide injection did not cause any change in renal antioxidant enzyme activity	

**Table 2b**

Recent experimental studies on oxidative stress markers related to CIN in humans.

Humans	Study design	Main findings related to ROS	Kidney function
289 consecutive patients with ST-segment elevation myocardial infarction undergoing primary percutaneous coronary intervention; Borekci et al. (2015)	Observational study for the relation of paraoxonase-1 activity and oxidative stress markers with contrast-induced nephropathy (CIN)	Paraoxonase-1 and total antioxidant status was significantly lower and oxidative stress index and total oxidant status concentrations were significantly higher in patients with CIN compared to the non-contrast-induced group	Paraoxonase-1 activity, oxidative stress index, contrast medium amount and diabetes were independent predictors for CIN in patients with anterior ST-segment elevation myocardial infarction
36 consecutive patients who underwent coronary angiography; Tajiri et al. (2011)	Observational study. Urinary F2-isoprostane, a marker of oxidative stress, measured at baseline and 24 h after angiography and serum creatinine (sCr) was measured at baseline, 24 h and after 1 year	In multivariate analysis, significant correlation found between the increase in urinary F2-isoprostane at 24 h and the decrease in estimated glomerular filtration rate (GFR) at 1 year	The decrease in estimated GFR at 1 year after coronary angiography correlated with the decrease in estimated GFR at 24 h after angiography
21 patients with reduced renal function who underwent coronary angiography; Saitoh et al. (2011)	Equally assigned to control, N-acetylcysteine (NAC) and glutathione	In controls, urinary lipid hydroperoxides increased to 299% of the baseline at 2 h after angiography. The increase in the urinary lipid hydroperoxides was abolished in the glutathione group, but not in the NAC group. In controls, serum glutathione level fell significantly 2 h after coronary angiography. The decrease was prevented in glutathione but not in NAC group	In the glutathione group, sCr level decreased significantly at 24 h after glutathione and returned to baseline level at 48 h, whereas it did not change in control or in NAC group
825 patients who underwent selective coronary angiography and/or intervention Wang, Wang, et al. (2015)	Randomized, placebo-controlled trial of reduced glutathione 1800 mg for the prevention of CIN	Change in serum malondialdehyde was not significant in the glutathione and in control group, change in serum total antioxidant capacity level was also similar in both groups	Incidence of contrast-induced AKI was 5.07% in the glutathione group and 4.97% in the control group (relative risk, 1.04)

However, not all of them have been rigorously confirmed (ACR Committee on Drugs and Contrast Media, 2016) and may act as confounders. On the other hand, there is a general agreement that the most important risk factor for CIN is pre-existing severe renal insufficiency (Davenport et al., 2013; Stacul et al., 2011).

CIN may occur in children but rarely (Ajami et al., 2010; Senthilnathan, Gauvreau, Marshall, Lock, & Bergersen, 2009). On the other hand, advanced age (>65 years) has been reported to be associated with a greater risk of CIN (Nicola et al., 2015). Nevertheless, there has been a discussion on whether age is a true risk factor because elderly individuals very often have an impaired renal function and other co-morbidities (Stacul et al., 2011).

The amount and type of CM used during coronary angiography or percutaneous coronary intervention has also been reported to affect the incidence of CIN. The nephrotoxic effect of iodinated CM may be proportional to dose for cardiac angiography; there is no evidence of a dose-toxicity relationship following intravenous administration when administered at usual diagnostic doses (ACR Committee on Drugs and Contrast Media, 2016). Administration of higher CM volumes is associated with increased CIN rate and mortality but in the absence of chronic kidney disease and diabetes mellitus, the incidence of CIN remains low (Aguilar-Souto et al., 2010; Kahn et al., 1990; Kane et al., 2008). The physicochemical properties of the CM (mainly osmolality and viscosity) have been reported to play a major role in their renal toxicity, as discussed above. Lowering the osmolality of the CM reduces the incidence of CIN. However, the issue of the "ideal CM" remains controversial, because the lower the osmolality of CM, the higher the viscosity (viscosity increases when shifting from high- to low- and isoosmolar CM (Azzalini, Spagnoli, & Ly, 2016; Seeliger et al., 2012). Administering a CM with high viscosity results in an increase of the viscosity of the renal ultra-filtrate and, therefore, to a parallel increased resistance to renal tubular flow, ultimately leading to tubular damage (Persson et al., 2005). Gadolinium-based CM either do not cause CIN, or exceptionally rarely, unless administered at (not recommended) extreme above-FDA-label doses to achieve X-ray attenuating effects during angiography (ACR Committee on Drugs and Contrast Media, 2016). In this case, gadolinium-based CM are more nephrotoxic than isoattenuating doses of iodinated CM (Briguori et al., 2006; Elmstahl et al., 2004; Erley et al., 2004).

Recently, literature on CIN has been dominated by reports on cardiac angiography with iodinated CM. However, in cardiac angiography the injection is intra-arterial and supra-renal; it requires a catheter that can dislodge atheroemboli and the CM dose to the kidneys is more abrupt and concentrated (Davenport et al., 2014; Karlsberg et al., 2011; Katzberg & Newhouse, 2010; Nyman, Almen, Jacobsson, & Aspelin, 2012) compared to interventions using intravenous CM. Inasmuch as the route of CM administration has been reported as a risk factor (intra-arterial compared to intravenous administration generally is associated with a higher risk of CIN) (Dong et al., 2012), the overall incidence of post-contrast AKI in studies of cardiac angiography is higher than it is in studies of intravenous iodinated CM administration. Consequently, data from cardiac angiography studies likely overestimate the risk of CIN for patients undergoing intravenous contrast-enhanced studies (Davenport et al., 2014; Katzberg & Newhouse, 2010).

Patients with chronic kidney disease are at increased risk of CIN, presumably because of reduced adaptive capacity but possibly also because of increased cellular exposure. If the same amount of CM is filtered by fewer nephrons, the exposure of the individual nephron will obviously increase proportionately (Hogstrom & Ikei, 2015; Stacul et al., 2011). The incidence of CIN in patients with pre-existing chronic kidney disease who underwent standard percutaneous coronary interventions has been reported as high as 55% (Rihal et al., 2002). It has also been shown that even though CM administration does not always cause CIN in cases with pre-existing renal insufficiency, major complications (death or renal failure requiring dialysis) occurred more frequently at long-term follow-up in patients with CM exposure than in those with no exposure (Abaci et al., 2015).

According to the American College of Radiology guidelines (ACR Committee on Drugs and Contrast Media, 2016) risk factors that may warrant renal function assessment prior to the administration of intravascular iodinated CM include: 1) age > 60 years; 2) history of renal disease (dialysis; kidney transplant; single kidney; renal cancer; renal surgery); 3) history of hypertension requiring medical therapy; 4) history of diabetes mellitus; and 5) metformin or metformin-containing drug combinations (metformin does not confer an increased risk of CIN but patients on metformin who develop AKI may be susceptible to lactic acidosis development). Patients without one of the above risk factors do not require a baseline sCr determination before iodinated CM



administration for a routine intravascular study. Recognition of these major risk factors facilitates identification of patients at increased risk for CIN and helps research efforts to evaluate the effectiveness of potential prevention strategies.

## 7. Prevention strategies for CIN

All patients receiving CM should be evaluated for the risk of CIN and high-risk patients should be considered for prevention strategies supported by clinical evidence. Because CIN is a potentially preventable clinical condition, an increased knowledge of CIN should increase the likelihood of reducing the risk of its occurrence. In patients without risk factors, the incidence of CIN appears to be minor (<1%) but in high-risk patients the incidence seems to be high (up to 15%) (Rancic, 2016).

### 7.1. Fluid therapy (volume expansion)

Hydration induces an increase of urine flow rate, reduces the concentration of CM in the tubule and expedites their excretion, thus reducing their bioavailability in the tubular cells. In that sense, time-dependent toxic effects are minimized (Ellis & Cohan, 2009). Hydration decreases the activity of the renin-angiotensin system causing a reduction in vasoconstrictive hormones, such as endothelin. Sodium diuresis is increased, while decreased tubulo-glomerular feedback further prevents tubular obstruction (Sterling et al., 2008). Diuresis also leads to vasodilation in the vulnerable region of the renal medulla possibly through an increase in the production of prostacyclin (Ellis & Cohan, 2009).

The use of hydration is widely accepted, because of its low cost and risk. Hydration (intravenous volume expansion) prior to the administration of CM is the intervention proven most effective in reducing CIN risk. It has become routine and is the standard against which all other potential preventive manoeuvres are compared regarding efficacy for CIN prevention in patients at risk (ACR Committee on Drugs and Contrast Media, 2016).

Isotonic sodium chloride (or isotonic sodium bicarbonate; see below) solution is the best option for preventing CIN. The reasons are not well established but the mechanism is likely related primarily to the increased tubular flow rates produced by volume expansion and, therefore, a decreased concentration of the filtered CM during transit through the kidney tubules and a slight increase in tubular pH resulting from a fixed acid excretion in an increased tubular volume produced by the increased tubular flow rates (Tasanarong, Burgess, et al., 2014).

For intravenous hydration, isotonic saline has been reported to be more effective than half-isotonic saline (saline-glucose) (Ellis & Cohan, 2009; Pattharanitima & Tasanarong, 2014). Fluid administration intravenously within 12 h before and 12 h after CM administration is superior to bolus administration at the time of injection (Ludwig & Keller, 2014). According to the American College of Radiology guidelines (ACR Committee on Drugs and Contrast Media, 2016), the ideal infusion rate-volume is not known, but isotonic fluids are preferred (Lactated Ringer's or 0.9% NaCl). One possible protocol would be 0.9% NaCl at 100 mL/h, beginning 6–12 h before and continuing 4–12 h after, but this is only practical in the inpatient setting (ACR Committee on Drugs and Contrast Media, 2016). The European Society of Urogenital Radiology guidelines recommends an intravenous regime of 1.0–1.5 mL/kg/h for at least 6 h before and after contrast medium administration (Stacul et al., 2011). According to the European Society of Cardiology/European Association for Cardio-Thoracic Surgery guidelines, all patients with chronic kidney disease (especially if estimated GFR is <40 mL/min/1.73 m<sup>2</sup>), who undergo diagnostic catheterization should receive preventive hydration with isotonic saline, starting around 12 h prior to angiography and continuing for at least 24 h afterwards to reduce the risk of CIN (Authors/Task Force members, 2014).

Apart from intravenous administration, hydration may be given orally. There has not been adequate research on this topic and results are conflicting (Stacul et al., 2011). A small recent meta-analysis of six randomized controlled trials concluded that the oral route may be as effective as the intravenous route for volume expansion for CIN prevention. However, the authors acknowledged that adequately powered trials with hard endpoints should be performed (Hiremath, Akbari, Shabana, Fergusson, & Knoll, 2013). Based on the overall current available evidence, oral hydration is considered less effective (ACR Committee on Drugs and Contrast Media, 2016).

Hydration is sometimes used in combination with several compounds such as diuretics (mannitol or furosemide) or agents with antioxidant properties (see below). An exacerbation of renal dysfunction is seen when furosemide is used in addition to intravenous saline solution (Kwok, Pang, Yeong, & Loke, 2013). Neither mannitol nor furosemide is recommended for CIN risk reduction (ACR Committee on Drugs and Contrast Media, 2016). However, according to the European Society of Cardiology/European Association for Cardio-Thoracic Surgery guidelines (Authors/Task Force members, 2014), furosemide with matched hydration may be considered over standard hydration in those at very high risk for CIN or in cases where prophylactic hydration before the procedure cannot be accomplished. The recommended protocol is initial 250 mL intravenous bolus of normal saline over 30 min (reduced to 150 mL in case of left ventricle dysfunction) followed by an intravenous bolus (0.25–0.5 mg/kg) of furosemide. When the urine output rate is >300 mL/h, patients undergo the coronary procedure. Matched fluid replacement is maintained during the procedure and for 4 h post-treatment.

A recent meta-analysis of randomized controlled trials evaluating the comparative effectiveness of interventions (administration of NAC, sodium bicarbonate, statins, or vitamin C (ascorbic acid)) that used intravenous or intra-arterial CM to reduce CIN in adults concluded that the greatest reduction in CIN rate was seen with intravenous saline plus NAC in patients receiving low-osmolar CM and with intravenous saline plus NAC plus statins (Subramaniam, Suarez-Cuervo, et al., 2016).

### 7.2. Antioxidants

As previously discussed, CM administration can cause an increase of ROS production in vasa recta and tubule cells and consequently induces apoptosis activation. Several compounds with antioxidant properties have been investigated including volume expansion using sodium bicarbonate, as well as pharmacological agents including NAC, ascorbic acid, statins, and recently, phosphodiesterase type 5 inhibitors (Table 3).

#### 7.2.1. Sodium bicarbonate

It has been proposed as an effective method of hydration, mainly due to its alkalinizing properties (Ellis & Cohan, 2009; Tasanarong, Burgess, et al., 2014). A reduction in oxidative stress in renal tubular cells may be the key mechanism of sodium bicarbonate nephroprotection. Bicarbonate is able to decelerate the Haber-Weiss reaction that generates free radicals. Bicarbonate may also directly scavenge peroxy-nitrite generated from nitric oxide. Urinary alkalinization and intra-tubular pH increase, as a direct effect of intravenous sodium bicarbonate administration, may reduce the pH-dependent generation of methemoglobin (Fe<sup>3+</sup>) in the tubular casts, the production of free radicals catalysed by ferrous-ion, as well as proteinuria-induced oxidative damage. Thus, attenuation of oxidative stress through urine alkalinization with sodium bicarbonate may attenuate CIN. The mechanism of action of sodium bicarbonate has mainly been deduced from animal studies but there are also data on its effectiveness in humans (Pavlidis, Jones, Sirkar, Mathur, & Smith, 2015; Schiffil, 2015).

Despite a large number of clinical trials and meta-analyses conducted so far, the most effective type of intravenous volume expansion (isotonic sodium bicarbonate versus sodium chloride) and the benefit of



**Table 3**  
Summary of the most common anti-oxidants studied for protection against contrast-induced nephropathy.

Anti-oxidant	Mode of action	Contraindications/side effects	Administration route
Sodium bicarbonate	Attenuation of oxidative stress through urine alkalization	Patients with moderate-to-severe chronic kidney disease	Intravenous
N-acetylcysteine	Scavenger of free radicals, vasodilation, precursor for glutathione synthesis, inhibit angiotensin-converting enzyme	Anaphylactoid reactions	Oral recommended
Ascorbic acid	Scavenger of oxygen free radicals	None reported	Oral
Statins	Pleiotropic action, improving endothelial function, maintaining nitric oxide production and reducing free radicals formation through NADPH oxidase activity	No contraindications	Oral
Phosphodiesterase 5 inhibitors (treatment of erectile dysfunction)	Enhancing the vasodilatory effect of released nitric oxide, selective inhibition of cyclic guanosine monophosphate (cGMP)-specific phosphodiesterase type 5	Various reported	Oral

NAC (see below; NAC) to prevent CIN is still unclear. Careful review of published trials reveals several methodological limitations contributing to their inconclusive findings. A carefully designed large multicentre double-blind randomized controlled trial (PRESERVE trial) is currently underway with the ambition to definitively answer these questions regarding the prevention of serious adverse outcomes associated with CIN in high-risk patients undergoing coronary or non-coronary angiography (Weisbord et al., 2013).

Some meta-analyses to date have shown intravenous volume expansion with sodium bicarbonate to be superior to normal saline (Jang et al., 2012; Merten et al., 2004; Navaneethan, Singh, Appasamy, Wing, & Sehgal, 2009), but these results have been challenged by other meta-analyses (Subramaniam, Wilson, et al., 2016; Zoungas et al., 2009) and cannot be considered definitive at this time. Intravenous sodium bicarbonate given 1 h before exposure to CM has been reported more effective in preventing CIN than isotonic saline and oral NAC given post-procedural (Kagan & Sheikh-Hamad, 2010). Furthermore, it has been reported that sodium bicarbonate is superior to saline for the prevention of CIN in patients with pre-existing renal insufficiency (Zhang, Liang, Chen, Liang, & Zhang, 2015), however this notion remains controversial (Caixeta & Mehran, 2010; Ellis & Cohan, 2009). Finally, the incidence of CIN has been reported to be significantly lower in sodium bicarbonate hydration with NAC compared to saline hydration with NAC and saline hydration with ascorbic acid plus NAC (Andreucci, Faga, Pisani, Sabbatini, Russo, et al., 2014; Pattharanitima & Tasanarong, 2014).

The European Society of Urogenital Radiology guidelines states that hydration with either isotonic saline or sodium bicarbonate (3 mL/kg/h for 1 h before contrast medium followed by 1 mL/kg/h for 6 h after) reduces the incidence of CIN (Stacul et al., 2011). However, according to the European Society of Cardiology/European Association for Cardio-Thoracic Surgery guidelines for patients with moderate-to-severe chronic kidney disease undergoing coronary angiography or multi-detector computed tomography, infusion of 0.84% sodium bicarbonate instead of standard hydration is not indicated (Authors/Task Force members, 2014).

### 7.2.2. NAC

NAC is an acetylated derivative of the amino acid cysteine. The potential of NAC as a protective agent of the kidney is promising because NAC carries both antioxidant and vasodilating properties as shown in animal studies and, therefore, it has been investigated as a preventive agent of CIN in humans (Fishbane, 2008; Hosseinjani, Moghaddas, & Khalili, 2013). It exerts significant protective/ameliorative effects against drug-induced renal injury in experimental models, attributed to several mechanisms in different experimental settings, including antioxidant action by restoring the reduced intracellular pool of the natural antioxidant glutathione; direct free radical scavenging; and/or interaction with ROS; as well as prevention of contrast-induced renal cell apoptosis (Briguori et al., 2011; Hosseinjani et al., 2013). Apart from the antioxidant properties, NAC exhibits other biological actions

that might be relevant in CIN prevention. It may have vasodilatory effects in certain situations, by stabilizing nitric oxide (Fishbane, 2008) or even by increasing nitric oxide production after the administration of CM (Briguori et al., 2011). In addition, the sulfhydryl group of NAC may inhibit angiotensin-converting enzyme, resulting in reduction of angiotensin II production (Fishbane, 2008).

NAC is available in oral and intravenous formulations, although bioavailability is very low. Following oral administration, bioavailability is reported to be <5%, probably due to extensive first-pass hepatic metabolism (only the oxidized form (no free drug) is detectable in very small quantities in the circulation); following intravenous administration, the drug is found highly bound to plasma/tissue proteins, forming various disulphide compounds with small amounts only detected in the circulation (Fishbane, 2008).

Due to the pharmacological properties of NAC, especially its poor bioavailability, the *in vivo* effects must be considered separately from its *in vitro* actions. The antioxidant effects of NAC may be indirect in humans (restoring via glutathione synthesis induction the reduced pool of intracellular glutathione that possesses a key role in the body defense against cellular oxidative damage; Rushworth & Megson, 2014). Circulating cysteine may enter renal cells serving as a precursor for glutathione production.

NAC has been widely used (mainly at a standard dose of 600 mg orally twice daily for 24 h the day before and on the day of the procedure; Stacul et al., 2011) for the prevention of CIN in populations at risk, following the publication of a milestone randomized placebo controlled trial (Tepel et al., 2000). The trial concluded that NAC (at 600 mg orally twice daily, prior to and after contrast administration), along with hydration (0.45% saline intravenously), prevents renal function reduction induced by non-ionic, low-osmolality contrast agents in patients with chronic renal insufficiency (Tepel et al., 2000). Subsequently, NAC has been studied at higher doses orally (1200 mg twice daily for 48 h) and intravenously (total dose ranging from 2400 mg to 150 mg/kg), but there have been widely conflicting results in a large number of clinical trials and meta-analyses and its efficacy to reduce CIN incidence remains controversial mainly due to methodological limitations contributing to the inconclusive findings (Owen, Hiremath, Myers, Fraser-Hill, & Barrett, 2014; Weisbord et al., 2013). A carefully designed multicentre double-blind randomized controlled trial (PRESERVE trial) is underway with the ambition to definitively answer this question among others (see above; sodium bicarbonate) in high-risk patients undergoing coronary or non-coronary angiography (Weisbord et al., 2013).

There have also been doubts about a potential artifactual effect on sCr concentration that may be responsible for the positive results seen because NAC reduces sCr concentration in normal volunteers without changing cystatin-C (a better marker of GFR than sCr), raising the possibility that it simply lowers sCr concentration without actually preventing CIN (Anderson, Park, & Patel, 2011).

A recent meta-analysis showed that NAC decreases the incidence of CIN in patients with pre-existing renal insufficiency but not in patients

with diabetes (Kang, Hu, Li, Ai, & Peng, 2015). A large recent meta-analysis (Subramaniam, Wilson, et al., 2016) showed that low-dose (1200 mg/day or less) and high-dose NAC (> 1200 mg/day) had a borderline, clinically-relevant effect and a small, not clinically-relevant effect, respectively, in reducing CIN compared to intravenous saline. A clinically important and statistically significant reduction in CIN was seen when NAC was compared with intravenous saline in patients receiving low-osmolar but not isoosmolar CM, with risk ratio estimates not differing between intravenous and intra-arterial routes of CM administration (Subramaniam, Wilson, et al., 2016). Finally, another large recent meta-analysis showed inverse and significant association between NAC supplementation and risk of CIN in patients undergoing coronary angiography and computed tomography, while a protective role in patients undergoing peripheral angiography was not obvious (Xu, Tao, Bai, Deng, & Chen, 2016).

NAC is inexpensive, readily available, easily administered, not associated with major adverse effects (except at high intravenous dose; risk of anaphylactic reaction; Anderson et al., 2011), and its use is generally not contraindicated because it rarely induces drug interactions (Owen et al., 2014; Wu et al., 2013). Nevertheless, at present the evidence of efficacy is not sufficient to recommend its use and it should not be considered a substitute for appropriate pre-procedural patient screening and adequate volume expansion (ACR Committee on Drugs and Contrast Media, 2016; Authors/Task Force members, 2014; Owen et al., 2014). Future research is needed to further define specific contexts in which patients could benefit from its use (Subramaniam, Wilson, et al., 2016).

### 7.2.3. Ascorbic acid

Due to the antioxidant properties of ascorbic acid, its efficacy in the prevention of oxidative stress-associated diseases has been studied extensively. Ascorbic acid is a safe, well-tolerated, and readily available antioxidant, which has been shown to attenuate renal damage in a CIN rat model (McCullough, Wolyn, Rocher, Levin, & O'Neill, 1997). Apart from scavenging oxygen free radicals that mediate cell necrosis after myocardial infarction and after angioplasty, ascorbic acid may also act as an antioxidant to inhibit ischemic cell death in the kidney (Zhou & Chen, 2012). However, conflicting results have been obtained in humans. It has been reported that prophylactic oral ascorbic acid administration may protect against CIN at a dosage of 3 g orally 2 h before the procedure and 2 g during the night and in the morning after the procedure (Spargias et al., 2004). In another study, patients receiving ascorbic acid had a 33% lower risk of developing CIN (Sadat, Usman, Gillard, & Boyle, 2013). In addition, when the patients underwent low-osmolar CM angiography with adequate hydration plus ascorbic acid, the incidence of CIN decreased significantly (Ali-Hassan-Sayegh et al., 2016). On the other hand, in patients with pre-existing renal dysfunction, no effect has been demonstrated (Boscheri et al., 2007). Oral, high-dose of ascorbic acid plus hydration could have antioxidant effects on renal function, in patients receiving low-osmolar CM, but does not decrease sCr concentration, and is not effective in patients with baseline renal insufficiency (Zhou & Chen, 2012). Another study showed no benefit over placebo, when standard dosages of ascorbic acid are administered intravenously the day before and the day of CM exposure in patients with renal insufficiency undergoing cardiac catheterization (Ali-Hassan-Sayegh et al., 2016).

### 7.2.4. Statins

Increasing evidence has demonstrated that statins can reduce the risk of CIN by means of non-lipid lowering (pleiotropic) effects on factors contributing to CIN progression, such as improving endothelial function, maintaining nitric oxide production, reducing inflammatory and immuno-modulatory processes, oxidative stress and platelet adhesion, that may contribute to both cardio- and nephro-protection even in the short-term (Leoncini, Toso, Maioli, Tropeano, & Bellandi, 2013; Yang, Wu, & Hu, 2015).

However, the actions of different statins (such as rosuvastatin and atorvastatin) are not the same. The differences might be associated with anti-inflammatory effects, low-density lipoprotein cholesterol lowering potency, nephroprotection and the effects on myocardial function (Liu, Liu, et al., 2014). The efficacy of statins for CIN prevention seems to be independent of lipophilicity of the statin tested (simvastatin, atorvastatin, and rosuvastatin) (Akyuz, Yaylak, Altay, Kasikcioglu, & Cam, 2015). In vitro, statins enhanced the production of heme oxygenase-1 protein, interfered with NADPH oxidase activity, diminished adhesion molecule expression and reduced free radical formation (Pattharanitima & Tasanarong, 2014). Pre-treatment of rats with statin appeared to attenuate the increase in sCr level and decreased the appearance of unfavourable histological findings in an ischemic-reperfusion injury model. Moreover, statins can attenuate CIN in a rat model through modulation of oxidative stress and pro-inflammatory cytokines (Pattharanitima & Tasanarong, 2014).

Currently, protocols for prevention of CIN in the United States do not include the use of statins. It may be time to reassess the role of statins in preventing CIN, especially because they are readily available, easy to administer, and relatively inexpensive. Statin therapy prevents the development of CIN in patients undergoing coronary angiography or percutaneous coronary intervention. All statin types tested had similar beneficial action, while the preventive action was most prominent in patients with chronic kidney disease, diabetes, congestive heart failure, those who received high volumes of CM, patients that are statin-naïve, and those with acute coronary syndrome (Gandhi, Mosleh, Abdel-Qadir, & Farkouh, 2014). In contrast, patients receiving rosuvastatin had a 51% lower risk of CIN compared to controls, however in chronic kidney disease patients undergoing CM exposure, rosuvastatin treatment showed no effect in preventing CIN (Yang et al., 2015). Statins may reduce CIN risk in low-risk patients with normal or slightly abnormal renal function but not in patients with moderate to severe renal dysfunction (Davenport, Cohan, & Ellis, 2015; Ukaigwe et al., 2014). The implementation of high-dose statin before diagnostic catheterization reduces the incidence of CIN and should be considered as an additional preventive measure in patients without contraindications (Authors/Task Force members, 2014).

In line with all recent meta-analyses on the comparison of statins versus intravenous saline (Li, Liu, Fu, Mei, & Dai, 2012; Li et al., 2016; Michael et al., 2014; Pappy, Stavrakis, Hennebry, & Abu-Fadel, 2011; Takagi & Umemoto, 2011; Zhang, Li, et al., 2011; Zhou, Yuan, Zhu, & Wang, 2011) except one (Zhang, Shen, et al., 2011), a large recent meta-analysis (Subramaniam, Wilson, et al., 2016) detected a clinically-important protective effect against CIN in populations with chronic kidney disease, diabetes mellitus, cardiac disease, and in general populations when statins were administered in combination with intravenous fluids compared with intravenous fluids alone, or in combination with NAC compared to NAC alone, but the effect was only statistically significant in the latter comparison. The authors concluded that apart from the fact that their findings provide moderate strength of evidence, there are also reasons to move forward with statins cautiously because all studies evaluating their effect to reduce the incidence of CIN have been performed using intra-arterial CM administration and, therefore, the protective effect against CIN for intravenous CM administration is unknown; it is also possible that the findings reported in the studies of statins could be partly explained by a direct effect on GFR that is independent of a protective effect on renal function (Subramaniam, Wilson, et al., 2016).

In summary, the current data regarding the efficacy of statins in CIN prophylaxis are inconclusive and there is insufficient evidence to generally support their use in radiology patients. Future research is needed to determine whether statins can reduce CIN in patients receiving intravenous CM (Subramaniam, Wilson, et al., 2016). However, according to the European Society of Cardiology/European Association for Cardio-Thoracic Surgery guidelines (Authors/Task Force members, 2014), for patients with moderate-to-severe chronic kidney disease undergoing

coronary angiography or multi-detector computed tomography short-term, high-dose therapy should be considered with rosuvastatin 40/20 mg or atorvastatin 80 mg or simvastatin 80 mg.

### 7.2.5. Phosphodiesterase 5 inhibitors

Drugs currently used for the treatment of erectile dysfunction in humans by enhancing the vasodilatory effect of released nitric oxide (sildenafil, tadalafil, vardenafil, and avanafil) could offer protection against CIN by sustaining the vasodilatory effect of nitric oxide. These drugs act by selective inhibition of the enzyme cyclic guanosine monophosphate (cGMP)-specific phosphodiesterase type 5 that metabolizes cGMP, the principal mediator of nitric oxide induced smooth-muscle relaxation and vasodilatation in the corpora cavernosa, and are collectively known as phosphodiesterase 5 inhibitors. However, the endogenous vasodilator nitric oxide is crucial for medullary oxygenation as well by enhancing regional blood flow (Morcos, 2014). The passage of CM through the kidney is associated with an increase in the metabolic activity of the renal outer medulla and medullary vasodilatory response is mediated by the release of prostanoids and nitric oxide. Decline in nitric oxide availability may intensify the hypoxic insult and contribute to the development of contrast-induced nephropathy. Prophylactic administration of a phosphodiesterase 5 inhibitor, particularly the long acting tadalafil, prior and after CM administration, therefore, offers a simple and rational approach to reduce the risk of contrast-induced nephropathy. This hypothesis warrants investigation to determine its clinical relevance (Morcos, 2014).

The protective effect of such drugs (mainly sildenafil and recently tadalafil) against CIN has been to date investigated in some animal studies (Choi et al., 2009; de Almeida et al., 2016; Lauver, Carey, Bergin, Lucchesi, & Gurm, 2014; Oruc et al., 2010; Ozbek et al., 2015). The effects of sildenafil on renal ischemia-reperfusion injury have been investigated in some animal models. In an experimental study of renal ischemia-reperfusion injury of male Sprague-Dawley rats (Choi et al., 2009), sildenafil showed anti-apoptotic effects in experimental ischemia-reperfusion renal injury via ERK phosphorylation, induction of iNOS and eNOS production, and a decrease in the Bax/Bcl-2 ratio. In another study on male Wistar albino rats, it was shown that pre-ischemic treatment with sildenafil can significantly attenuate ischemia/-reperfusion-induced renal injury by decreasing leukocyte infiltration (Oruc et al., 2010).

Furthermore, the protective effect of sildenafil has been evaluated in a rabbit model (New Zealand white rabbits) of contrast-induced AKI (Lauver et al., 2014). The drug was administered before CM infusion and repeatedly thereafter. Animals were euthanized after 48 h. Intravenous CM administration produced marked kidney injury. sCr concentrations were elevated within 2 h of the infusion and remained elevated thereafter. Renal histological evaluation revealed significant tubular necrosis. The effects of the CM were dose dependent. Treatment with sildenafil was associated with a lower degree of histological injury, attenuation in markers of AKI and reduction in electrolyte ( $K^+$ ) derangement. These results suggested a possible role for sildenafil in the treatment of contrast-induced AKI, warranting further evaluation to determine the exact mechanism of protection.

In a recent animal study, male Wistar rats were divided into control, CIN, and CIN pre-treated with sildenafil (de Almeida et al., 2016). Renal function was evaluated (GFR, renal blood flow, sCr, uraemia, and proteinuria) and oxidative stress was assessed by flow cytometry for intracellular ROS. Sildenafil treatment in the CIN group attenuated the marked reduction of GFR and renal blood flow; it reduced sCr, uraemia, and proteinuria, while flow cytometry demonstrated attenuation of ROS production. These data suggest that sildenafil may be a new therapeutic agent to prevent CIN by preserving renal function and attenuating oxidative stress.

Finally, another study, has recently investigated the effect of tadalafil in preventing CIN in female Wistar albino rats (Ozbek et al., 2015). After 48 h of dehydration, CM (megluminediatrozoate) was administered to

the first group; CM with tadalafil was administered to the second group, while the third group served as controls. Blood and tissue samples were taken 48 h after the procedure. Serum cystatin C, sCr and blood urea nitrogen (BUN) values were significantly lower in the CM plus tadalafil group compared to the CM only group. Serum and tissue malondialdehyde concentrations were significantly lower in the CM plus tadalafil group than in the CM only group. These results demonstrated the protective effect of tadalafil in the prevention of CIN in rats.

## 8. Conclusions

The exact pathophysiology of CIN remains obscure. Consequences of CIN can be devastating, especially in the vulnerable subgroups of the general population. However, the need for contrast-based medical examinations and interventions is constantly increasing. All patients should be evaluated for CIN risk and an individualized risk-benefit strategy prepared. Intravenous volume expansion using isotonic fluids prior to CM administration is the intervention proven most effective. The value of using compounds with antioxidant properties other than sodium bicarbonate remains controversial, warranting further clinical investigation.

## Conflict of interest statement

The authors declare that there are no conflicts of interest.

## References

- Abaci, O., Harmankaya, O., Kocas, B., Kocas, C., Bostan, C., Coskun, U., et al. (2015). Long-term follow-up of patients at high risk for nephropathy after contrast exposure. *Angiology* 66, 514–518.
- Abujudeh, H. H., Gee, M. S., & Kaewlai, R. (2009). In emergency situations, should serum creatinine be checked in all patients before performing second contrast CT examinations within 24 hours? *Journal of the American College of Radiology* 6, 268–273.
- ACR Committee on Drugs and Contrast Media (2016). *ACR manual on contrast media* (10.2 ed.). American College of Radiology.
- Aguiar-Souto, P., Ferrante, G., Del Furia, F., Barlis, P., Khurana, R., & Di Mario, C. (2010). Frequency and predictors of contrast-induced nephropathy after angioplasty for chronic total occlusions. *International Journal of Cardiology* 139, 68–74.
- Ajami, G., Derakhshan, A., Amoozgar, H., Mohamadi, M., Borzouee, M., Basiratnia, M., et al. (2010). Risk of nephropathy after consumption of nonionic contrast media by children undergoing cardiac angiography: A prospective study. *Pediatric Cardiology* 31, 668–673.
- Akdeniz, D., Celik, H. T., Kazanci, F., Yilmaz, H., Yalcin, S., Bilgic, M. A., et al. (2015). Is kidney injury molecule 1 a valuable tool for the early diagnosis of contrast-induced nephropathy? *Journal of Investigative Medicine* 63, 930–934.
- Akyuz, S., Yaylak, B., Altay, S., Kasikcioglu, H., & Cam, N. (2015). The role of statins in preventing contrast-induced acute kidney injury: A narrative review. *Angiology* 66, 701–707.
- Ali-Hassan-Sayegh, S., Mirhosseini, S. J., Ghodrati-pour, Z., Sarafan-Chaharsoughi, Z., Dehghan, A. M., Rahimizadeh, E., et al. (2016). Protective effects of anti-oxidant supplementations on contrast-induced nephropathy after coronary angiography: An updated and comprehensive meta-analysis and systematic review. *Kardiologia Polska* 74, 610–626.
- Anderson, S. M., Park, Z. H., & Patel, R. V. (2011). Intravenous N-acetylcysteine in the prevention of contrast media-induced nephropathy. *The Annals of Pharmacotherapy* 45, 101–107.
- Andreucci, M., Faga, T., Pisani, A., Sabbatini, M., & Michael, A. (2014a). Acute kidney injury by radiographic contrast media: Pathogenesis and prevention. *BioMed Research International* 2014, 362725.
- Andreucci, M., Faga, T., Pisani, A., Sabbatini, M., Russo, D., & Michael, A. (2014b). Prevention of contrast-induced nephropathy through a knowledge of its pathogenesis and risk factors. *Scientific World Journal* 2014, 823169.
- Ari, E., Kedrah, A. E., Alahdab, Y., Bulut, G., Eren, Z., Baytekin, O., et al. (2012). Antioxidant and renoprotective effects of paricalcitol on experimental contrast-induced nephropathy model. *The British Journal of Radiology* 85, 1038–1043.
- Authors/Task Force members (2014). 2014 ESC/EACTS guidelines on myocardial revascularization: The Task Force on Myocardial Revascularization of the European Society of Cardiology (ESC) and the European Association for Cardio-Thoracic Surgery (EACTS) developed with the special contribution of the European Association of Percutaneous Cardiovascular Interventions (EAPCI). *European Heart Journal* 35, 2541–2619.
- Azzalini, L., Spagnoli, V., & Ly, H. Q. (2016). Contrast-induced nephropathy: From pathophysiology to preventive strategies. *The Canadian Journal of Cardiology* 32, 247–255.
- Barrett, B. J., & Carlisle, E. J. (1993). Meta-analysis of the relative nephrotoxicity of high- and low-osmolality iodinated contrast media. *Radiology* 188, 171–178.
- Barrett, B. J., & Parfrey, P. S. (2006). Clinical practice. Preventing nephropathy induced by contrast medium. *The New England Journal of Medicine* 354, 379–386.



- Baumgarten, D. A., & Ellis, J. H. (2008). Contrast-induced nephropathy: Contrast material not required? *American Journal of Roentgenology* 191, 383–386.
- Baykara, M., Silici, S., Ozelcik, M., Guler, O., Erdogan, N., & Bilgen, M. (2015). In vivo nephroprotective efficacy of propolis against contrast-induced nephropathy. *Diagnostic and Interventional Radiology* 21, 317–321.
- Boa, I. S., Porto, M. L., Pereira, A. C., Ramos, J. P., Scherer, R., Oliveira, J. P., et al. (2015). Resin from *Virola oleifera* protects against radioccontrast-induced nephropathy in mice. *PLoS One* 10, e0144329.
- Borekci, A., Gur, M., Turkoglu, C., Cayli, M., Selek, S., Kaypakli, O., et al. (2015). Oxidative stress and paraoxonase 1 activity predict contrast-induced nephropathy in patients with ST-segment elevation myocardial infarction undergoing primary percutaneous coronary intervention. *Angiology* 66, 339–345.
- Boscheri, A., Weinbrenner, C., Botzek, B., Reynen, K., Kuhlisch, E., & Strasser, R. H. (2007). Failure of ascorbic acid to prevent contrast-media induced nephropathy in patients with renal dysfunction. *Clinical Nephrology* 68, 279–286.
- Boyacioglu, M., Turgut, H., Akgullu, C., Eryilmaz, U., Kum, C., & Onbasili, O. A. (2014). The effect of L-carnitine on oxidative stress responses of experimental contrast-induced nephropathy in rats. *The Journal of Veterinary Medical Science* 76, 1–8.
- Briguori, C., Colombo, A., Airoldi, F., Melzi, G., Michev, I., Carlino, M., et al. (2006). Gadolinium-based contrast agents and nephrotoxicity in patients undergoing coronary artery procedures. *Catheterization and Cardiovascular Interventions* 67, 175–180.
- Briguori, C., Donnarumma, E., Quintavalle, C., Fiore, D., & Condorelli, G. (2015). Contrast-induced acute kidney injury: Potential new strategies. *Current Opinion in Nephrology and Hypertension* 24, 145–153.
- Briguori, C., Quintavalle, C., De Micco, F., & Condorelli, G. (2011). Nephrotoxicity of contrast media and protective effects of acetylcysteine. *Archives of Toxicology* 85, 165–173.
- Briguori, C., Quintavalle, C., Donnarumma, E., & Condorelli, G. (2014). Novel biomarkers for contrast-induced acute kidney injury. *BioMed Research International* 2014, 568738.
- Caiazza, A., Russo, L., Sabbatini, M., & Russo, D. (2014). Hemodynamic and tubular changes induced by contrast media. *BioMed Research International* 2014, 578974.
- Caixeta, A., & Mehran, R. (2010). Evidence-based management of patients undergoing PCI: Contrast-induced acute kidney injury. *Catheterization and Cardiovascular Interventions* 75(Suppl. 1), S15–S20.
- Cetin, M., Devrim, E., Serin Kilicoglu, S., Erguder, I. B., Namuslu, M., Cetin, R., et al. (2008). Ionic high-osmolar contrast medium causes oxidant stress in kidney tissue: Partial protective role of ascorbic acid. *Renal Failure* 30, 567–572.
- Chatterjee, P. K., Brown, P. A., Cuzzocrea, S., Zacharowski, K., Stewart, K. N., Mota-Filipe, H., et al. (2001). Calpain inhibitor-1 reduces renal ischemia/reperfusion injury in the rat. *Kidney International* 59, 2073–2083.
- Choi, D. E., Jeong, J. Y., Lim, B. J., Chung, S., Chang, Y. K., Lee, S. J., et al. (2009). Pretreatment of sildenafil attenuates ischemia-reperfusion renal injury in rats. *American Journal of Physiology. Renal Physiology* 297, F362–F370.
- Chousterman, B. G., Bouadma, L., Moutereau, S., Loric, S., Alvarez-Gonzalez, A., Mekontso-Dessap, A., et al. (2013). Prevention of contrast-induced nephropathy by N-acetylcysteine in critically ill patients: Different definitions, different results. *Journal of Critical Care* 28, 701–709.
- Colbay, M., Yuksel, S., Usulan, I., Acarturk, G., Karaman, O., Bas, O., et al. (2010). Novel approach for the prevention of contrast nephropathy. *Experimental and Toxicologic Pathology* 62, 81–89.
- Davenport, M. S., Cohan, R. H., & Ellis, J. H. (2015). Contrast media controversies in 2015: Imaging patients with renal impairment or risk of contrast reaction. *American Journal of Roentgenology* 204, 1174–1181.
- Davenport, M. S., Cohan, R. H., Khalatbari, S., & Ellis, J. H. (2014). The challenges in assessing contrast-induced nephropathy: Where are we now? *American Journal of Roentgenology* 202, 784–789.
- Davenport, M. S., Khalatbari, S., Cohan, R. H., Dillman, J. R., Myles, J. D., & Ellis, J. H. (2013). Contrast material-induced nephrotoxicity and intravenous low-osmolality iodinated contrast material: Risk stratification by using estimated glomerular filtration rate. *Radiology* 268, 719–728.
- de Almeida, L. S., Barboza, J. R., Freitas, F. P., Porto, M. L., Vasquez, E. C., Meyrelles, S. S., et al. (2016). Sildenafil prevents renal dysfunction in contrast media-induced nephropathy in Wistar rats. *Human & Experimental Toxicology* (Jan 20. pii: 0960327115626582). Epub ahead of print.
- de Caestecker, M., Humphreys, B. D., Liu, K. D., Fissell, W. H., Cerda, J., Nolin, T. D., et al. (2015). Bridging translation by improving preclinical study design in AKI. *Journal of the American Society of Nephrology* 26, 2905–2916.
- Detrenis, S., Meschi, M., Musini, S., & Savazzi, G. (2005). Lights and shadows on the pathogenesis of contrast-induced nephropathy: State of the art. *Nephrology, Dialysis, Transplantation* 20, 1542–1550.
- Dong, M., Jiao, Z., Liu, T., Guo, F., & Li, G. (2012). Effect of administration route on the renal safety of contrast agents: A meta-analysis of randomized controlled trials. *Journal of Nephrology* 25, 290–301.
- Dorval, J. F., Dixon, S. R., Zelman, R. B., Davidson, C. J., Rudko, R., & Resnic, F. S. (2013). Feasibility study of the RenalGuard balanced hydration system: A novel strategy for the prevention of contrast-induced nephropathy in high risk patients. *International Journal of Cardiology* 166, 482–486.
- Ellis, J. H., & Cohan, R. H. (2009). Prevention of contrast-induced nephropathy: An overview. *Radiologic Clinics of North America* 47, 801–811.
- Elmstahl, B., Nyman, U., Leander, P., Chai, C. M., Frennby, B., & Almen, T. (2004). Gadolinium contrast media are more nephrotoxic than a low osmolar iodine medium employing doses with equal X-ray attenuation in renal arteriography: An experimental study in pigs. *Academic Radiology* 11, 1219–1228.
- Endre, Z. H., & Pickering, J. W. (2010). Outcome definitions in non-dialysis intervention and prevention trials in acute kidney injury (AKI). *Nephrology, Dialysis, Transplantation* 25, 107–118.
- Erley, C. M., Bader, B. D., Berger, E. D., Tuncel, N., Winkler, S., Tepe, G., et al. (2004). Gadolinium-based contrast media compared with iodinated media for digital subtraction angiography in azeotemic patients. *Nephrology, Dialysis, Transplantation* 19, 2526–2531.
- Fishbane, S. (2008). N-acetylcysteine in the prevention of contrast-induced nephropathy. *Clinical Journal of the American Society of Nephrology* 3, 281–287.
- Gandhi, S., Mosleh, W., Abdel-Qadir, H., & Farkouh, M. E. (2014). Statins and contrast-induced acute kidney injury with coronary angiography. *The American Journal of Medicine* 127, 987–1000.
- Goldenberg, I., & Matetzky, S. (2005). Nephropathy induced by contrast media: Pathogenesis, risk factors and preventive strategies. *CMAJ* 172, 1461–1471.
- Golshahi, J., Nasri, H., & Gharipour, M. (2014). Contrast-induced nephropathy; a literature review. *Journal of Nephropathology* 3, 51–56.
- Han, W. K., Bailly, V., Abichandani, R., Thadhani, R., & Bonventre, J. V. (2002). Kidney Injury Molecule-1 (KIM-1): A novel biomarker for human renal proximal tubule injury. *Kidney International* 62, 237–244.
- Heyman, S. N., Rosenberger, C., Rosen, S., & Khamaisi, M. (2013). Why is diabetes mellitus a risk factor for contrast-induced nephropathy? *BioMed Research International* 2013, 123589.
- Hiremath, S., Akbari, A., Shabana, W., Fergusson, D. A., & Knoll, G. A. (2013). Prevention of contrast-induced acute kidney injury: Is simple oral hydration similar to intravenous? A systematic review of the evidence. *PLoS One* 8, e60009.
- Hogstrom, B., & Ilkei, N. (2015). Physicochemical properties of radiographic contrast media, potential nephrotoxicity and prophylaxis. *Clinical and Experimental Pharmacology & Physiology* 42, 1251–1257.
- Hosseinjani, H., Moghaddas, A., & Khalili, H. (2013). N-acetylcysteine for the prevention of non-contrast media agent-induced kidney injury: From preclinical data to clinical evidence. *European Journal of Clinical Pharmacology* 69, 1375–1390.
- Hsu, D. Z., Li, Y. H., Chu, P. Y., Periasamy, S., & Liu, M. Y. (2011). Sesame oil prevents acute kidney injury induced by the synergistic action of aminoglycoside and iodinated contrast in rats. *Antimicrobial Agents and Chemotherapy* 55, 2532–2536.
- Ishihara, M., Urushido, M., Hamada, K., Matsumoto, T., Shimamura, Y., Ogata, K., et al. (2013). Sestrin-2 and BNIP3 regulate autophagy and mitophagy in renal tubular cells in acute kidney injury. *American Journal of Physiology. Renal Physiology* 305, F495–F509.
- Jang, J. S., Jin, H. Y., Seo, J. S., Yang, T. H., Kim, D. K., Kim, T. H., et al. (2012). Sodium bicarbonate therapy for the prevention of contrast-induced acute kidney injury – A systematic review and meta-analysis. *Circulation Journal* 76, 2255–2265.
- Jost, G., Lengsfeld, P., Lenhard, D. C., Pietsch, H., Hutter, J., & Sieber, M. A. (2011). Viscosity of iodinated contrast agents during renal excretion. *European Journal of Radiology* 80, 373–377.
- Jost, G., Pietsch, H., Lengsfeld, P., Hutter, J., & Sieber, M. A. (2010). The impact of the viscosity and osmolality of iodine contrast agents on renal elimination. *Investigative Radiology* 45, 255–261.
- Kagan, A., & Sheikh-Hamad, D. (2010). Contrast-induced kidney injury: Focus on modifiable risk factors and prophylactic strategies. *Clinical Cardiology* 33, 62–66.
- Kahn, J. K., Rutherford, B. D., McConahay, D. R., Johnson, W. L., Giorgi, L. V., Shimshak, T. M., et al. (1990). High-dose contrast agent administration during complex coronary angioplasty. *American Heart Journal* 120, 533–536.
- Kane, G. C., Doyle, B. J., Lerman, A., Barsness, G. W., Best, P. J., & Rihal, C. S. (2008). Ultra-low contrast volumes reduce rates of contrast-induced nephropathy in patients with chronic kidney disease undergoing coronary angiography. *Journal of the American College of Cardiology* 51, 89–90.
- Kang, X., Hu, D. Y., Li, C. B., Ai, Z. S., & Peng, A. (2015). N-acetylcysteine for the prevention of contrast-induced nephropathy in patients with pre-existing renal insufficiency or diabetes: A systematic review and meta-analysis. *Renal Failure* 37, 297–303.
- Karlsberg, R. P., Dohad, S. Y., Sheng, R., & Iodixanol Peripheral Computed Tomographic Angiography Study Investigator, P. (2011). Contrast medium-induced acute kidney injury: Comparison of intravenous and intraarterial administration of iodinated contrast medium. *Journal of Vascular and Interventional Radiology* 22, 1159–1165.
- Katsiki, N., Athyros, V. G., Karagiannis, A., & Mikhailidis, D. P. (2015). Contrast-induced nephropathy: An “all or none” phenomenon? *Angiology* 66, 508–513.
- Katzberg, R. W., & Newhouse, J. H. (2010). Intravenous contrast medium-induced nephrotoxicity: Is the medical risk really as great as we have come to believe? *Radiology* 256, 21–28.
- Keaney, J. J., Hannon, C. M., & Murray, P. T. (2013). Contrast-induced acute kidney injury: How much contrast is safe? *Nephrology, Dialysis, Transplantation* 28, 1376–1383.
- Kooiman, J., van de Peppel, W. R., Sijpkens, Y. W., Brulez, H. F., de Vries, P. M., Nicolaie, M. A., et al. (2015). No increase in Kidney Injury Molecule-1 and Neutrophil Gelatinase-Associated Lipocalin excretion following intravenous contrast enhanced-CT. *European Radiology* 25, 1926–1934.
- Kurtoglu, T., Durmaz, S., Akgullu, C., Gungor, H., Eryilmaz, U., Meteoglu, I., et al. (2015). Ozone preconditioning attenuates contrast-induced nephropathy in rats. *The Journal of Surgical Research* 195, 604–611.
- Kwok, C. S., Pang, C. L., Yeong, J. K., & Loke, Y. K. (2013). Measures used to treat contrast-induced nephropathy: Overview of reviews. *The British Journal of Radiology* 86, 20120272.
- Lakhal, K., Ehrmann, S., Chaari, A., Laissy, J. P., Regnier, B., Wolff, M., et al. (2011). Acute Kidney Injury Network definition of contrast-induced nephropathy in the critically ill: Incidence and outcome. *Journal of Critical Care* 26, 593–599.
- Lauver, D. A., Carey, E. G., Bergin, I. L., Lucchesi, B. R., & Gurm, H. S. (2014). Sildenafil citrate for prophylaxis of nephropathy in an animal model of contrast-induced acute kidney injury. *PLoS One* 9, e113598.
- Lee, H. C., Yen, H. W., & Sheu, S. H. (2006). Effects of different contrast media on glutathione peroxidase and superoxide dismutase activities in the heart and kidneys of



- normal and streptozotocin-induced diabetic rats. *Journal of the Formosan Medical Association* 105, 530–535.
- Lenhard, D. C., Pietsch, H., Sieber, M. A., Ernst, R., Lengsfeld, P., Ellinghaus, P., et al. (2012). The osmolality of nonionic, iodinated contrast agents as an important factor for renal safety. *Investigative Radiology* 47, 503–510.
- Leoncini, M., Toso, A., Maioli, M., Tropeano, F., & Bellandi, F. (2013). Statin treatment before percutaneous coronary intervention. *Journal of Thoracic Disease* 5, 335–342.
- Li, Y., Liu, Y., Fu, L., Mei, C., & Dai, B. (2012). Efficacy of short-term high-dose statin in preventing contrast-induced nephropathy: A meta-analysis of seven randomized controlled trials. *PLoS One* 7, e34450.
- Li, H., Wang, C., Liu, C., Li, R., Zou, M., & Cheng, G. (2016). Efficacy of short-term statin treatment for the prevention of contrast-induced acute kidney injury in patients undergoing coronary angiography/percutaneous coronary intervention: A meta-analysis of 21 randomized controlled trials. *American Journal of Cardiovascular Drugs* 16, 201–219.
- Liu, Y., Liu, Y. H., Tan, N., Chen, J. Y., Zhou, Y. L., Li, L. W., et al. (2014a). Comparison of the efficacy of rosuvastatin versus atorvastatin in preventing contrast induced nephropathy in patient with chronic kidney disease undergoing percutaneous coronary intervention. *PLoS One* 9, e111124.
- Liu, Z. Z., Schmerbach, K., Lu, Y., Perlewitz, A., Nikitina, T., Cantow, K., et al. (2014b). Iodinated contrast media cause direct tubular cell damage, leading to oxidative stress, low nitric oxide, and impairment of tubuloglomerular feedback. *American Journal of Physiology. Renal Physiology* 306, F864–F872.
- Ludwig, U., & Keller, F. (2014). Prophylaxis of contrast-induced nephrotoxicity. *BioMed Research International* 2014, 308316.
- Mathai, J. P., Germain, M., & Shore, G. C. (2005). BH3-only BIK regulates BAX, BAK-dependent release of Ca<sup>2+</sup> from endoplasmic reticulum stores and mitochondrial apoptosis during stress-induced cell death. *The Journal of Biological Chemistry* 280, 23829–23836.
- McClennan, B. L. (1990). Preston M. Hickey memorial lecture. Ionic and nonionic iodinated contrast media: Evolution and strategies for use. *American Journal of Roentgenology* 155, 225–233.
- McCullough, P. A., & Brown, J. R. (2011). Effects of intra-arterial and intravenous iso-osmolar contrast medium (iodixanol) on the risk of contrast-induced acute kidney injury: A meta-analysis. *Cardiovascular Medicine* 1, 220–234.
- McCullough, P. A., Wolyn, R., Rocher, L. L., Levin, R. N., & O'Neill, W. W. (1997). Acute renal failure after coronary intervention: Incidence, risk factors, and relationship to mortality. *The American Journal of Medicine* 103, 368–375.
- McDonald, J. S., McDonald, R. J., Carter, R. E., Katzberg, R. W., Kallmes, D. F., & Williamson, E. E. (2014). Risk of intravenous contrast material-mediated acute kidney injury: A propensity score-matched study stratified by baseline-estimated glomerular filtration rate. *Radiology* 271, 65–73.
- McDonald, J. S., McDonald, R. J., Comin, J., Williamson, E. E., Katzberg, R. W., Murad, M. H., et al. (2013). Frequency of acute kidney injury following intravenous contrast medium administration: A systematic review and meta-analysis. *Radiology* 267, 119–128.
- Mehta, R. L., Kellum, J. A., Shah, S. V., Molitoris, B. A., Ronco, C., Warnock, D. G., et al. (2007). Acute Kidney Injury Network: Report of an initiative to improve outcomes in acute kidney injury. *Critical Care* 11, R31.
- Merten, G. J., Burgess, W. P., Gray, L. V., Holliman, J. H., Roush, T. S., Kowalchuk, G. J., et al. (2004). Prevention of contrast-induced nephropathy with sodium bicarbonate: A randomized controlled trial. *JAMA* 291, 2328–2334.
- Michael, A., Giacoppo, D., Capodanno, D., Capranzano, P., Aruta, P., & Tamburino, C. (2014). Meta-analysis of randomized controlled trials of preprocedural statin administration for reducing contrast-induced acute kidney injury in patients undergoing coronary catheterization. *BioMed Research International* 114, 541–548.
- Morcós, S. K. (2014). Can selective inhibitors of cyclic guanosine monophosphate (cGMP)-specific phosphodiesterase type 5 (PDE 5) offer protection against contrast induced nephropathy? *Quantitative Imaging in Medicine and Surgery* 4, 214–215.
- Navaneethan, S. D., Singh, S., Appasamy, S., Wing, R. E., & Sehgal, A. R. (2009). Sodium bicarbonate therapy for prevention of contrast-induced nephropathy: A systematic review and meta-analysis. *American Journal of Kidney Diseases* 53, 617–627.
- Naziroglu, M., Yoldas, N., Uzgur, E. N., & Kayan, M. (2013). Role of contrast media on oxidative stress, Ca(2+) signaling and apoptosis in kidney. *The Journal of Membrane Biology* 246, 91–100.
- Newhouse, J. H., & RoyChoudhury, A. (2013). Quantitating contrast medium-induced nephropathy: Controlling the controls. *Radiology* 267, 4–8.
- Nicola, R., Shaqdan, K. W., Aran, K., Mansouri, M., Singh, A., & Abujudeh, H. H. (2015). Contrast-induced nephropathy: Identifying the risks, choosing the right agent, and reviewing effective prevention and management methods. *Current Problems in Diagnostic Radiology* 44, 501–504.
- Nyman, U., Almen, T., Jacobsson, B., & Aspelin, P. (2012). Are intravenous injections of contrast media really less nephrotoxic than intra-arterial injections? *European Radiology* 22, 1366–1371.
- Oruc, O., Inci, K., Aki, F. T., Zeybek, D., Muftuoglu, S. F., Kilinc, K., et al. (2010). Sildenafil attenuates renal ischemia reperfusion injury by decreasing leukocyte infiltration. *Acta Histochemica* 112, 337–344.
- Owen, R. J., Hiremath, S., Myers, A., Fraser-Hill, M., & Barrett, B. J. (2014). Canadian Association of Radiologists consensus guidelines for the prevention of contrast-induced nephropathy: Update 2012. *Canadian Association of Radiologists Journal* 65, 96–105.
- Ozbek, K., Ceyhan, K., Koc, F., Sogut, E., Altunkas, F., Karayakali, M., et al. (2015). The protective effect of single dose tadalafil in contrast-induced nephropathy: An experimental study. *Anatolian Journal of Cardiology* 15, 306–310.
- Pannu, N., Wiebe, N., Tonelli, M., & Alberta Kidney Disease, N. (2006). Prophylaxis strategies for contrast-induced nephropathy. *JAMA* 295, 2765–2779.
- Pappy, R., Stavrakis, S., Hennebry, T. A., & Abu-Fadel, M. S. (2011). Effect of statin therapy on contrast-induced nephropathy after coronary angiography: A meta-analysis. *International Journal of Cardiology* 151, 348–353.
- Pattharanitima, P., & Tسانarong, A. (2014). Pharmacological strategies to prevent contrast-induced acute kidney injury. *BioMed Research International* 2014, 236930.
- Pavlidis, A. N., Jones, D. A., Sirker, A., Mathur, A., & Smith, E. J. (2015). Prevention of contrast-induced acute kidney injury after percutaneous coronary intervention for chronic total coronary occlusions. *The American Journal of Cardiology* 115, 844–851.
- Peltier, J., Bellocq, A., Perez, J., Doublier, S., Dubois, Y. C., Haymann, J. P., et al. (2006). Calpain activation and secretion promote glomerular injury in experimental glomerulonephritis: Evidence from calpastatin-transgenic mice. *Journal of the American Society of Nephrology* 17, 3415–3423.
- Persson, P. B., Hansell, P., & Liss, P. (2005). Pathophysiology of contrast medium-induced nephropathy. *Kidney International* 68, 14–22.
- Pisani, A., Riccio, E., Andreucci, M., Faga, T., Ashour, M., Di Nuzzi, A., et al. (2013). Role of reactive oxygen species in pathogenesis of radiocontrast-induced nephropathy. *BioMed Research International* 2013, 868321.
- Pisani, A., Sabbatini, M., Riccio, E., Rossano, R., Andreucci, M., Capasso, C., et al. (2014). Effect of a recombinant manganese superoxide dismutase on prevention of contrast-induced acute kidney injury. *Clinical and Experimental Nephrology* 18, 424–431.
- Ramponi, S., Grotti, A., Morisetti, A., Vultaggio, S., & Lorusso, V. (2007). Effects of iodinated contrast media on endothelium: An in vitro study. *Toxicology In Vitro* 21, 191–196.
- Rancic, Z. S. (2016). Commentary on “Contrast induced nephropathy and long-term renal decline after percutaneous transluminal angioplasty for symptomatic peripheral arterial disease”. *European Journal of Vascular and Endovascular Surgery* 51, 394.
- Rewa, O., & Bagshaw, S. M. (2014). Acute kidney injury-epidemiology, outcomes and economics. *Nature Reviews. Nephrology* 10, 193–207.
- Rezaee, M. A., Mohammadpour, A. H., Imenshahidi, M., Mahmoudi, M., Sankian, M., Tsarouhas, K., et al. (2016). Protective effect of erythropoietin on myocardial apoptosis in rats exposed to carbon monoxide. *Life Sciences* 148, 118–124.
- Rihal, C. S., Textor, S. C., Grill, D. E., Berger, P. B., Ting, H. H., Best, P. J., et al. (2002). Incidence and prognostic importance of acute renal failure after percutaneous coronary intervention. *Circulation* 105, 2259–2264.
- Romano, G., Briguori, C., Quintavalle, C., Zanca, C., Rivera, N. V., Colombo, A., et al. (2008). Contrast agents and renal cell apoptosis. *European Heart Journal* 29, 2569–2576.
- Rushworth, G. F., & Megson, I. L. (2014). Existing and potential therapeutic uses for N-acetylcysteine: The need for conversion to intracellular glutathione for antioxidant benefits. *Pharmacology & Therapeutics* 141, 150–159.
- Russo, D., Aurelio, A., & Durante, A. (2014). Contrast-induced nephropathy in percutaneous coronary interventions: Pathogenesis, risk factors, outcome, prevention and treatment. *BioMed Research International* 128, 62–72.
- Sadat, U., Usman, A., Gillard, J. H., & Boyle, J. R. (2013). Does ascorbic acid protect against contrast-induced acute kidney injury in patients undergoing coronary angiography: A systematic review with meta-analysis of randomized, controlled trials. *Journal of the American College of Cardiology* 62, 2167–2175.
- Saito, H. (2013). Toxicopharmacological perspective of the Nrf2-Keap1 defense system against oxidative stress in kidney diseases. *Biochemical Pharmacology* 85, 865–872.
- Saitoh, T., Satoh, H., Nobuhara, M., Machii, M., Tanaka, T., Ohtani, H., et al. (2011). Intravenous glutathione prevents renal oxidative stress after coronary angiography more effectively than oral N-acetylcysteine. *Heart and Vessels* 26, 465–472.
- Schiff, H. (2015). Sodium bicarbonate infusion for prevention of acute kidney injury: No evidence for superior benefit, but risk for harm? *International Urology and Nephrology* 47, 321–326.
- Scoditti, E., Massaro, M., & Montinari, M. R. (2013). Endothelial safety of radiological contrast media: Why being concerned. *Vascular Pharmacology* 58, 48–53.
- Seeliger, E., Becker, K., Ladwig, M., Wronski, T., Persson, P. B., & Flemming, B. (2010). Up to 50-fold increase in urine viscosity with iso-osmolar contrast media in the rat. *Radiology* 256, 406–414.
- Seeliger, E., Flemming, B., Wronski, T., Ladwig, M., Arakelyan, K., Godes, M., et al. (2007). Viscosity of contrast media perturbs renal hemodynamics. *Journal of the American Society of Nephrology* 18, 2912–2920.
- Seeliger, E., Sendeski, M., Rihal, C. S., & Persson, P. B. (2012). Contrast-induced kidney injury: Mechanisms, risk factors, and prevention. *European Heart Journal* 33, 2007–2015.
- Senthilnathan, S., Gauvreau, K., Marshall, A. C., Lock, J. E., & Bergersen, L. (2009). Contrast administration in pediatric cardiac catheterization: Dose and adverse events. *Catheterization and Cardiovascular Interventions* 73, 814–820.
- Solomon, R. (2014). Contrast media: Are there differences in nephrotoxicity among contrast media? *BioMed Research International* 2014, 934947.
- Spargias, K., Alexopoulos, E., Kyrzopoulos, S., Iokovis, P., Greenwood, D. C., Manginas, A., et al. (2004). Ascorbic acid prevents contrast-mediated nephropathy in patients with renal dysfunction undergoing coronary angiography or intervention. *Circulation* 110, 2837–2842.
- Stacul, F., van der Molen, A. J., Reimer, P., Webb, J. A., Thomsen, H. S., Morcos, S. K., et al. (2011). Contrast induced nephropathy: Updated ESUR Contrast Media Safety Committee guidelines. *European Radiology* 21, 2527–2541.
- Sterling, K. A., Tehrani, T., & Rudnick, M. R. (2008). Clinical significance and preventive strategies for contrast-induced nephropathy. *Current Opinion in Nephrology and Hypertension* 17, 616–623.
- Subramaniam, R. M., Suarez-Cuervo, C., Wilson, R. F., Turban, S., Zhang, A., Sherrod, C., et al. (2016b). Effectiveness of prevention strategies for contrast-induced nephropathy: A systematic review and meta-analysis. *Annals of Internal Medicine* 164, 406–416.
- Subramaniam, R. M., Wilson, R. F., Turban, S., Suarez-Cuervo, C., Zhang, A., Sherrod, C., et al. (2016a). Contrast-induced nephropathy: Comparative effectiveness of preventive measures [internet]. *AHRQ comparative effectiveness reviews, report no. 15(16)-EHC023-EF*.
- Susantitaphong, P., & Eiam-Ong, S. (2014). Nonpharmacological strategies to prevent contrast-induced acute kidney injury. *BioMed Research International* 2014, 463608.

- Tajiri, K., Maruyama, H., Sato, A., Shimojo, N., Saito, T., Endo, M., et al. (2011). Prediction of chronic renal insufficiency after coronary angiography by an early increase in oxidative stress and decrease in glomerular filtration rate. *Circulation Journal* 75, 437–442.
- Takagi, H., & Umemoto, T. (2011). A meta-analysis of randomized trials for effects of periprocedural atorvastatin on contrast-induced nephropathy. *International Journal of Cardiology* 153, 323–325.
- Tasanarong, A., Burgess, W. P., & Walker, P. J. (2014b). Mechanisms of contrast-induced nephropathy reduction for saline (NaCl) and sodium bicarbonate (NaHCO<sub>3</sub>). *BioMed Research International* 2014, 510385.
- Tasanarong, A., Kongkham, S., & Itharat, A. (2014a). Antioxidant effect of *Phyllanthus emblica* extract prevents contrast-induced acute kidney injury. *BMC Complementary and Alternative Medicine* 14, 138.
- Tepel, M., van der Giet, M., Schwarzfeld, C., Laufer, U., Liermann, D., & Zidek, W. (2000). Prevention of radiographic-contrast-agent-induced reductions in renal function by acetylcysteine. *The New England Journal of Medicine* 343, 180–184.
- Trivedi, H., & Foley, W. D. (2010). Contrast-induced nephropathy after a second contrast exposure. *Renal Failure* 32, 796–801.
- Tumlin, J., Stacul, F., Adam, A., Becker, C. R., Davidson, C., Lameire, N., et al. (2006). Pathophysiology of contrast-induced nephropathy. *The American Journal of Cardiology* 98, 14K–20K.
- Ueda, J., Nygren, A., Hansell, P., & Ulfendahl, H. R. (1993). Effect of intravenous contrast media on proximal and distal tubular hydrostatic pressure in the rat kidney. *Acta Radiologica* 34, 83–87.
- Ukaigwe, A., Karmacharya, P., Mahmood, M., Pathak, R., Aryal, M. R., Jalota, L., et al. (2014). Meta-analysis on efficacy of statins for prevention of contrast-induced acute kidney injury in patients undergoing coronary angiography. *The American Journal of Cardiology* 114, 1295–1302.
- Wang, C., Wang, W., Ma, S., Lu, J., Shi, H., & Ding, F. (2015a). Reduced glutathione for prevention of renal outcomes in patients undergoing selective coronary angiography or intervention. *Journal of Interventional Cardiology* 28, 249–256.
- Wang, N., Wei, R. B., Li, Q. P., Yang, X., Li, P., Huang, M. J., et al. (2015b). Renal protective effect of probucol in rats with contrast-induced nephropathy and its underlying mechanism. *Medical Science Monitor* 21, 2886–2892.
- Wang, F., Zhang, G., Zhou, Y., Gui, D., Li, J., Xing, T., et al. (2014). Magnolin protects against contrast-induced nephropathy in rats via antioxidation and antiapoptosis. *Oxidative Medicine and Cellular Longevity* 2014, 203458.
- Weisbord, S. D., Gallagher, M., Kaufman, J., Cass, A., Parikh, C. R., Chertow, G. M., et al. (2013). Prevention of contrast-induced AKI: A review of published trials and the design of the prevention of serious adverse events following angiography (PRESERVE) trial. *Clinical Journal of the American Society of Nephrology* 8, 1618–1631.
- Weisbord, S. D., & Palevsky, P. M. (2015). Contrast-associated acute kidney injury. *Critical Care Clinics* 31, 725–735.
- Westhoff, J. H., Seibert, F. S., Waldherr, S., Bauer, F., Tonshoff, B., Fichtner, A., et al. (2017). Urinary calprotectin, kidney injury molecule-1, and neutrophil gelatinase-associated lipocalin for the prediction of adverse outcome in pediatric acute kidney injury. *European Journal of Pediatrics* 176, 745–755.
- Wi, J., Ko, Y. G., Kim, J. S., Kim, B. K., Choi, D., Ha, J. W., et al. (2011). Impact of contrast-induced acute kidney injury with transient or persistent renal dysfunction on long-term outcomes of patients with acute myocardial infarction undergoing percutaneous coronary intervention. *Heart* 97, 1753–1757.
- Wu, M. Y., Hsiang, H. F., Wong, C. S., Yao, M. S., Li, Y. W., Hsiang, C. Y., et al. (2013). The effectiveness of N-acetylcysteine in preventing contrast-induced nephropathy in patients undergoing contrast-enhanced computed tomography: A meta-analysis of randomized controlled trials. *International Urology and Nephrology* 45, 1309–1318.
- Xu, R., Tao, A., Bai, Y., Deng, Y., & Chen, G. (2016). Effectiveness of N-acetylcysteine for the prevention of contrast-induced nephropathy: A systematic review and meta-analysis of randomized controlled trials. *Journal of the American Heart Association* 5, e003968.
- Yang, Y., Wu, Y. X., & Hu, Y. Z. (2015). Rosuvastatin treatment for preventing contrast-induced acute kidney injury after cardiac catheterization: A meta-analysis of randomized controlled trials. *Medicine (Baltimore)* 94, e1226.
- Zhang, B. C., Li, W. M., & Xu, Y. W. (2011a). High-dose statin pretreatment for the prevention of contrast-induced nephropathy: A meta-analysis. *The Canadian Journal of Cardiology* 27, 851–858.
- Zhang, B., Liang, L., Chen, W., Liang, C., & Zhang, S. (2015). The efficacy of sodium bicarbonate in preventing contrast-induced nephropathy in patients with pre-existing renal insufficiency: A meta-analysis. *BMJ Open* 5, e006989.
- Zhang, T., Shen, L. H., Hu, L. H., & He, B. (2011b). Statins for the prevention of contrast-induced nephropathy: A systematic review and meta-analysis. *American Journal of Nephrology* 33, 344–351.
- Zhao, Z., Liao, G., Zhou, Q., Lv, D., Holthfer, H., & Zou, H. (2016). Sulforaphane attenuates contrast-induced nephropathy in rats via Nrf2/HO-1 pathway. *Oxidative Medicine and Cellular Longevity* 2016, 9825623.
- Zhao, B., Zhao, Q., Li, J., Xing, T., Wang, F., & Wang, N. (2015). Renalase protects against contrast-induced nephropathy in Sprague-Dawley rats. *PLoS One* 10, e0116583.
- Zhou, L., & Chen, H. (2012). Prevention of contrast-induced nephropathy with ascorbic acid. *Internal Medicine* 51, 531–535.
- Zhou, Y., Yuan, W. J., Zhu, N., & Wang, L. (2011). Short-term, high-dose statins in the prevention of contrast-induced nephropathy: A systematic review and meta-analysis. *Clinical Nephrology* 76, 475–483.
- Zoungas, S., Ninomiya, T., Huxley, R., Cass, A., Jardine, M., Gallagher, M., et al. (2009). Systematic review: Sodium bicarbonate treatment regimens for the prevention of contrast-induced nephropathy. *Annals of Internal Medicine* 151, 631–638.